

Clinical Analysis and Strategy for Liver Transplantation in Patients with Pre-existing Portal Vein Thrombosis

Tsung-Han Wu^{1,2}, MD; Yann-Sheng Lin¹, MD; Chen-Fang Lee^{1,2}, MD;
Ting-Jung Wu^{1,2}, MD; Ming-Chin Yu¹, MD; Kun-Ming Chan^{1,2}, MD;
Wei-Chen Lee^{1,2}, MD

Background: Liver transplantation (LT) in patients with portal vein thrombosis (PVT) remains a challenge for transplant surgeons. In this study, we included a group of patients with PVT who underwent LT, and analyzed patient outcomes.

Methods: A total of 356 patients who underwent LT consisting of 167 cases of deceased donor LT and 189 cases of live donor LT at Chang Gung Memorial Hospital Linkou Medical Center between September 1996 and June 2009 were retrospectively reviewed; 24 (6.7%) of these patients had PVT at transplantation. Their clinical features, surgical management, and outcomes were analyzed.

Results: Surgical management of patients with PVT included a thrombectomy followed by direct anastomosis between the recipient's and the liver graft portal vein (PV) ($n = 13$), interposition vein graft between the recipient's coronary vein (CV) and the liver graft PV ($n = 3$), direct anastomosis of the recipient's CV and the liver graft PV ($n = 1$), interposition jump graft from the recipient's superior mesenteric vein to the liver graft PV ($n = 4$), and transection of the thrombotic PV followed by interposition of a venous graft between the recipient's PV and the liver graft PV ($n = 3$). There were 7 hospital mortalities. The mean follow-up for the 17 surviving patients was 36.3 months (range, 3.4–105.1 months), and 14 patients were still alive at the end of the study. Four patients (16.7%) had rethrombosis of portal inflow after LT. Patients with PVT undergoing LT had a significantly higher mortality rate ($p = 0.033$) than patients without PVT undergoing LT. However, there was no significant difference in the cumulative survival rates ($p = 0.0696$). Further analysis of patient survival according to PVT grade, venous graft application, and reconstructed portal flow routes also exhibited no significant differences.

Conclusions: LT for patients with PVT is clinically feasible and should not be considered a contraindication. However, a favorable outcome is achievable only with ideal surgical management to overcome PVT during LT.

(*Chang Gung Med J* 2011;34:426-34)

Key words: portal vein thrombosis, liver transplantation, surgical management, outcome

From the ¹Department of General Surgery; ²Chang Gung Transplantation Institute, Chang Gung Memorial Hospital at Linkou, Chang Gung University College of Medicine, Taoyuan, Taiwan.

Received: Aug. 24, 2010; Accepted: Dec. 31, 2010

Correspondence to: Dr. Kun-Ming Chan, Chang Gung Transplantation Institute, Chang Gung Memorial Hospital at Linkou, 5, Fusing St., Gueishan Township, Taoyuan County 333, Taiwan (R.O.C.) Tel.: 886-3-3281200 ext. 3366; Fax: 886-3-3285818; E-mail: chankunming@cgmh.org.tw

Portal vein thrombosis (PVT) is a common complication of chronic liver disease with an incidence that varies between 0.6% and 15.8%.⁽¹⁻⁴⁾ The occurrence of PVT is complex and multifactorial, and the majority of patients have associated liver cirrhosis. In the initial era of liver transplantation (LT), PVT was considered as an absolute contraindication. However, innovations in surgical techniques and the use of aggressive approaches have made it possible to overcome PVT during LT, which is currently the only way to cure patients with end-stage liver disease and concurrent PVT. Nonetheless, the preoperative condition and extensive collateral circulation of these patients also render LT very complicated, and the complexity of the involved surgical techniques remains a challenge for transplant surgeons. The most important issue is the reconstruction of the portal system, for which several available surgical techniques have been proposed to ensure restoration of adequate portal flow during LT.^(5,6)

In this study, we collected data and retrospectively reviewed our center's LT experience with PVT patients. Surgical management and patient outcomes were also investigated.

METHODS

Patients and transplantation

A total of 356 patients who received LT consisting of 167 cases of deceased donor LT (DDLT) and 189 cases of live donor LT (LDLT) at Chang Gung Memorial Hospital, Linkou Medical Center in Taiwan between September 1996 and June 2009 were retrospectively reviewed under the approval of the institution's review board.

Of these, 24 patients were intraoperatively confirmed as having PVT, none of whom were diagnosed with malignant thrombosis. Their medical records, including clinical characteristics, surgical management, and outcomes were further examined.

Patients were thoroughly examined for any contraindications to liver transplantation before being placed on the waitlist. The pretransplantation examinations included biochemical analysis, imaging survey, and immunological tests. If patients were initially diagnosed with PVT, dedicated liver magnetic resonance imaging (MRI) or dynamic computed tomography (CT) was performed to exclude malignant PVT. All LTs at our institution were performed using

standard techniques without venovenous bypass. The venous outflow of the liver graft was restored by end-to-side anastomosis of the donor's hepatic vein to the recipient's inferior vena cava (IVC) or a piggy-back technique of side-to-side anastomosis between the recipient's and graft IVCs. The liver graft was reperfused after the portal vein (PV) anastomosis and the hepatic artery was reconstructed using microsurgical techniques. In LDLT, a cryopreserved venous graft recovered from the iliac vein of a deceased donor was used for reconstruction of venous outflow and the PV whenever indicated, as previously described.⁽⁷⁻⁹⁾

The degree and extent of PVT was intraoperatively assessed and classified according to the grading system proposed by Yerdel et al. as follows: grade 1, < 50% thrombosis of the vessel lumen with or without minimal obstruction of the superior mesenteric vein (SMV); grade 2, \geq 50% thrombosis of the vessel lumen or total occlusion of the PV; grade 3, complete PV and proximal SMV thrombosis; and grade 4, occlusive thrombosis with extension to the distal SMV.⁽⁶⁾

Patency and flow of the reconstructed PV were checked with a Transonic Flowmeter (Transonic System Inc. Ithaca, NY, U.S.A.) following the completion of vascular reconstruction and prior to closure of the abdominal wall. Doppler ultrasonography was routinely performed every other day during the first week after transplantation and biweekly thereafter or whenever clinically indicated. Additionally, patients were routinely followed up with dynamic liver CT 1 month after the operation and ultrasonography at 3-month intervals. Laboratory data including liver function tests and hematological tests were closely checked every day during hospitalization and every month thereafter. None of the recipients received antithrombosis treatment. However, a prostaglandin was administered for maintenance of hepatic artery and portal venous flow immediately after LT for 5 to 7 days.

Statistical analysis

All data were analyzed using the statistical software SPSS 13.0 (SPSS Inc. Chicago, IL, U.S.A.). We applied χ^2 or Fisher's exact tests to analyze categorical data, and logistic regression was performed for multivariate analysis. Survival was measured from the time of transplantation until death or the

last follow-up, and all causes of death were included in the analysis of overall survival. Survival curves were constructed using the Kaplan-Meier method and compared with the log-rank test. A *p* value of less than 0.05 was considered statistically significant.

RESULTS

Clinical features of patients

The transplantations consisted of 6 DDLTs and 18 LDLTs, with the recipients' ages ranging from 19 to 63 years (mean \pm SD, 51.8 \pm 10.0). Seven patients had grade 1 PVT, 11 patients had grade 2, and 6 patients had grade 3. Surgical management of PVT included a thrombectomy followed by anastomosis of the recipient and graft PVs (*n* = 13), interposition venous graft between the recipients' coronary vein (CV) and the graft PV (*n* = 3), anastomosis of the recipient's CV and the graft PV (*n* = 1), interposition jump graft of the recipient's SMV to the graft PV (*n* = 4), and transection of the thrombotic PV followed by interposition of the venous graft between the recipient's PV and the graft PV (*n* = 3).

Seven patients died within 3 months, resulting in a hospital mortality rate of 29%. One of these patients died on post-transplantation day 7 of PV rethrombosis leading to graft failure because of poor quality of the recipient's PV and vascular graft. One patient died of acute rejection. The remaining 5 deaths were related to posttransplantation infection. The median follow-up period for the remaining patients was 31.6 months (range, 3.4–105.1 months), and 14 patients remained alive at the end of this study. During the follow-up, no PV stenosis occurred in any patient but rethrombosis of the PV or its tributary veins was noted in 3 patients. Two of these patients initially underwent a thrombectomy followed by primary anastomosis of the PV; 1 patient had received an interposition venous graft between the donor and recipient PV at transplantation. The 3 episodes of rethrombosis occurred 3, 4, 6 months after transplantation. All rethromboses were mild and were located in the proximal SMV without involving the main portal trunk; all patients were in a good condition and did not require intervention.

Table 1 lists the clinical characteristics of patients undergoing LT and compares those with and without pre-existing PVT. There were no significant differences in the clinical features between patients

Table 1. Comparison of Clinical Features in Patients with and without PVT undergoing Liver Transplantation

Characteristics	PVT n = 24 (%)	Non-PVT n = 332 (%)	<i>p</i> value
Age (mean \pm SD)	52.0 \pm 10.0	48.5 \pm 13.6	0.219
Sex (male: female)	19:5	240:92	0.465
Virus hepatitis			0.762
HBV	12 (50%)	195 (58.7%)	
HCV	4 (16.7%)	58 (17.5%)	
Both HBV & HCV	2 (8.3%)	18 (5.4%)	
None	6 (25%)	61 (18.4%)	
MELD score			0.198
< 20	17 (70.8%)	136 (52.9%)	
20–40	6 (25.0%)	113 (44.1%)	
> 40	1 (4.2%)	8 (3.1%)	
Indication for transplantation			0.614
Hepatocellular carcinoma	7 (29.2%)	122 (36.7%)	
Virus-associated liver cirrhosis	11 (45.8%)	143 (43.1%)	
Alcoholic liver cirrhosis	3 (12.5%)	15 (4.5%)	
Wilson's disease	1 (4.2%)	9 (2.7%)	
Biliary cirrhosis	1 (4.2%)	19 (5.7%)	
Acute hepatic failure	0 (0%)	13 (3.9%)	
others	1 (4.2%)	11 (3.3%)	
Liver transplantation type			0.026
DDLT	6 (25%)	161 (48.5%)	
LDLT	18 (75%)	171 (51.5%)	
Hospital mortality	7 (29.2%)	42 (12.7%)	0.033

Abbreviations: PVT: portal vein thrombosis; SD: standard deviation; HBV: hepatitis B virus; HCV: hepatitis C virus; MELD: model for end-stage liver disease; DDLT: deceased donor liver transplantation; LDLT: living donor liver transplantation.

with and without PVT at transplantation. Nonetheless, significant differences in the LT type (*p* = 0.026) and hospital mortality rate (*p* = 0.033) were observed in patients with PVT compared with those without PVT (Table 1). Multivariate analysis also showed significant differences in these two factors between the two groups (Table 2). However, further analysis of mortality causes showed no significant differences between these two groups (Table 3). Moreover, in contrast to patients with pre-existing PVT, none of the patients without pre-existing PVT encountered PV thrombosis during the follow-up period after LT.

Table 2. Multivariate Logistic Regression Analysis of Significant Factors

Factors	Odds ratio (95% CI)	<i>p</i> value
Liver transplantation type (DLT/DDLTL)	3.247 (1.230-8.567)	0.017
Hospital mortality (with/ without)	3.435 (1.305-9.042)	0.012

Abbreviations: DDLT: deceased donor liver transplantation; DLT: living donor liver transplantation.

Table 3. Comparison of Causes leading to Hospital Mortality between LT Patients with and without PVT

Causes	PVT <i>n</i> = 7 (%)	Non-PVT <i>n</i> = 42 (%)	<i>p</i> value
Re-thrombosis of portal inflow	1 (14.3%)	0	0.142
Internal bleeding	0	8 (19.0%)	0.581
Infection	5 (71.4%)	17 (40.5%)	0.219
Graft failure	0	5 (11.9%)	1.000
Acute rejection	1 (14.3%)	6 (14.3%)	1.000
Others	0	6 (14.3%)	

Abbreviation: PVT: portal vein thrombosis.

Survival of patients

The cumulative overall survival rates of patients with PVT undergoing LT were 62.5%, 58.6%, and 58.6% at 1, 3, and 5 years, respectively, which indicated borderline statistically significant differences from the overall survival rates of patients without PVT, which were 77.2%, 73.3% and 71.1% at 1, 3, and 5 years, respectively ($p = 0.0696$, Fig. 1).

Subsequently, the outcomes of patients with PVT undergoing LT were further analyzed according to thrombosis grade and surgical management. The comparison of survival curves with regard to PVT grade revealed similar outcomes in all 3 grades with 5-year survival rates of 64.3%, 54.5%, and 50% for grades 1, 2, and 3, respectively ($p = 0.7244$, Fig. 2A). The outcomes of patients using cryopreserved vascular grafts for reconstruction of the PV were not statistically different from those not using these grafts, revealing 5-year survival rates of 59.5% and 50%, respectively ($p = 0.5961$, Fig. 2B).

The patient survival curves were also compared with regard to route of reconstructed portal flow i.e.,

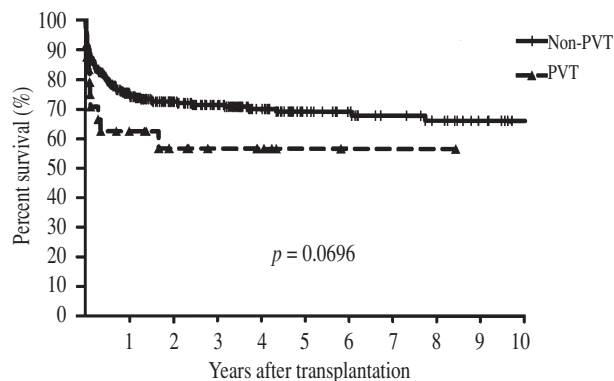


Fig. 1 Overall cumulative survival rates of patients with ($n = 24$) and without ($n = 332$) PVT undergoing liver transplantation. The survival curves were not significantly different between the 2 groups ($p = 0.0696$).

the anatomical route with anastomosis of the PV between the liver graft and recipient, and alternative routes with portal flow bypassing the original portal route and going either through the CV or from an SMV interposition jump graft to the liver graft. The 5-year survival rates were 58.9% for the anatomical route versus 50% for the alternative route, with no significant differences between the 2 curves ($p = 0.6868$, Fig. 2C).

DISCUSSION

Although PVT was considered an absolute contraindication for LT in the early 1980s, advances in surgical techniques and perioperative management have overcome this obstacle. Several groups have reported favorable results in patients with PVT undergoing LT, and have described effective strategies for the management of PVT during LT.⁽¹⁰⁻¹³⁾ PVT is, therefore, no longer a contraindication for LT. However, information on this issue remains relatively limited. We therefore conducted the current study to obtain additional data to aid in the management of this complication.

The pathophysiology of PVT is complex, but it appears to be related to liver cirrhosis, which causes elevation of portal pressure associated with endothelial injury and thrombus formation.^(14,15) The incidence of PVT during LT has been reported to range from 2.1% to 26%.^(6,16) Nonetheless, the rate of PVT in cirrhotic patients is estimated to be as high as

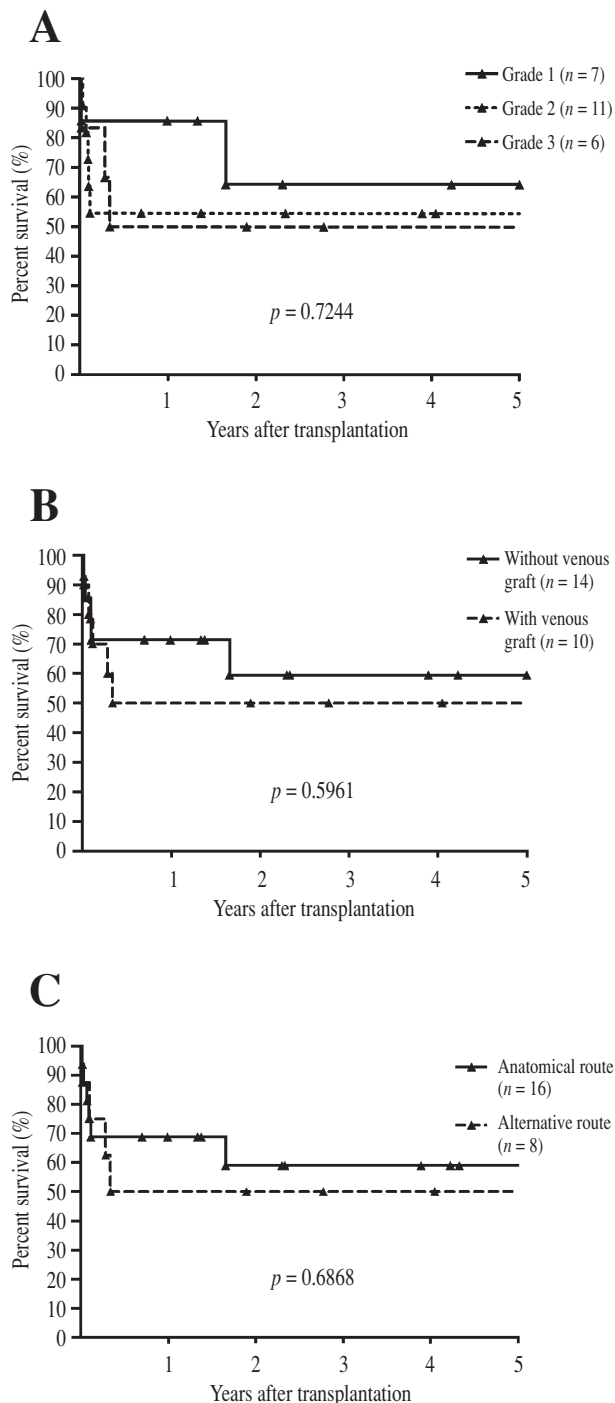


Fig. 2 Comparison of cumulative survival curves among patients with PVT receiving liver transplantation according to Yerdel grade of PVT (A, $p = 0.7244$), application of venous grafts (B, $p = 0.5961$), and route of reconstructed portal flow (C, $p = 0.6868$). None of the comparisons revealed significant differences.

64%, depending on the diagnostic method and the definition of PVT.^(14,15) Therefore, it is expected that transplantation surgeons will encounter more patients with PVT in the future.

The rate of PVT was only 6.7% among patients undergoing LT, and no cases of grade 4 PVT were observed in the present study. This might be because of patient selection and the small number of LTs in our series. Patients with grade 4 PVT usually have associated complications, including massive ascites and collateral vascular circulation.^(6,13) Although several effective surgical methods have been proposed for the treatment of grade 4 PVT,^(5,15) they potentially render LT more technically difficult and increase the associated morbidity. In addition, the extent of PVT appears to influence the outcomes of patients undergoing LT.^(6,13,16) Therefore, although LT in patients with grade 4 PVT is feasible, the decision to perform the procedure should only be made after careful consideration of the transplantation center's experience and the patient's clinical status. Moreover, the mortality risk in cirrhotic patients with PVT who did not receive LT has been reported to be 2.6 times higher than that in patients without PVT.⁽¹⁷⁾ Thus, LT should be considered as soon as possible for patients with PVT.

With a 1-year survival rate of 62.5%, the present results are comparable with previous reports that showed 1-year survival rates of 57% to 87% in patients with PVT undergoing LT.⁽⁵⁾ Nonetheless, the present results are similar to a recent study, which indicated that recipients with PVT had a significantly higher risk of mortality versus recipients without PVT.⁽¹⁷⁾ This suggests that LT in patients with PVT remains hazardous. In contrast, the long-term outcome of patients with PVT undergoing LT was comparable with that of patients without PVT according to the current study and other series.⁽¹²⁾ The borderline statistically significant difference in survival curves might be related to a generally high mortality rate in patients with PVT; otherwise, the long term outcome in these 2 groups would be similar. Moreover, comparisons of patient outcomes with regard to the use of venous grafts, reconstruction routes, and PVT grades did not exhibit any differences, suggesting that the method used to reconstruct the PV does not affect a patient's outcome as long as effective portal flow is obtained during LT.

Although the hospital mortality rates reflected

significant differences between patients with and without pre-existing PVT undergoing LT, a further analysis of the cause of hospital mortalities revealed that the mortalities in both groups were mostly due to post-transplantation infection, which is a common cause of hospital mortality after LT. Therefore, the difference observed could be attributed to the relatively small sample size of patients with PVT. A larger number of patients or a more detailed analysis of the pathophysiology or immunity of patients with PVT might be necessary to clarify these results. However, the reason for the differences in LT type is not completely explained by the data available for the present analysis; this warrants further large-scale investigations as well.

The occurrence of malignant thrombosis in cirrhotic patients concurrent with hepatocellular carcinoma (HCC) is possible, and these patients should be excluded from candidacy for transplantation. Recently, advances in diagnostic tools including liver dynamic CT, MRI, and contrast-enhanced ultrasonography have increased the diagnostic accuracy of PVT. Nonetheless, false negatives in patients with low-grade PVT can occur,⁽¹⁰⁾ and surgeons should be able to overcome this situation during LT. Therefore, if patients with HCC are considered for LT, it is advisable to determine with certainty which PVTs

are not malignant thromboses.

Another concern in transplantation in patients with PVT is postoperative PV rethrombosis. It has been reported that 6.2% to 28.6% of patients experience PV rethrombosis after LT.⁽¹⁸⁻²⁰⁾ In the present study, rethrombosis was identified in 4 patients (16.7%). Severe rethrombosis can also lead to a high incidence of mortality, as was observed in one patient in the present study.⁽⁶⁾ However, the use of venous grafts has been shown to result in a higher incidence of rethrombosis following reconstruction of the PV conduit, without affecting either the liver graft or patient outcome.⁽²¹⁾ The present results also suggest that cryopreserved venous grafts can be used safely and without negatively impacting the survival of the liver graft and patient. Utilization of anticoagulation therapy to prevent PV rethrombosis after LT remains controversial, but it could be considered in high risk patients or for recanalization of PVT after LT.⁽²²⁾

Taken together, depending on PVT grading and the experience of the surgeon, various surgical techniques can be performed to restore adequate portal flow to liver grafts. According to our analysis and a review of literature, we propose a simplified algorithm for the surgical management of PVT during liver transplantation (Fig. 3). Briefly, a thrombecto-

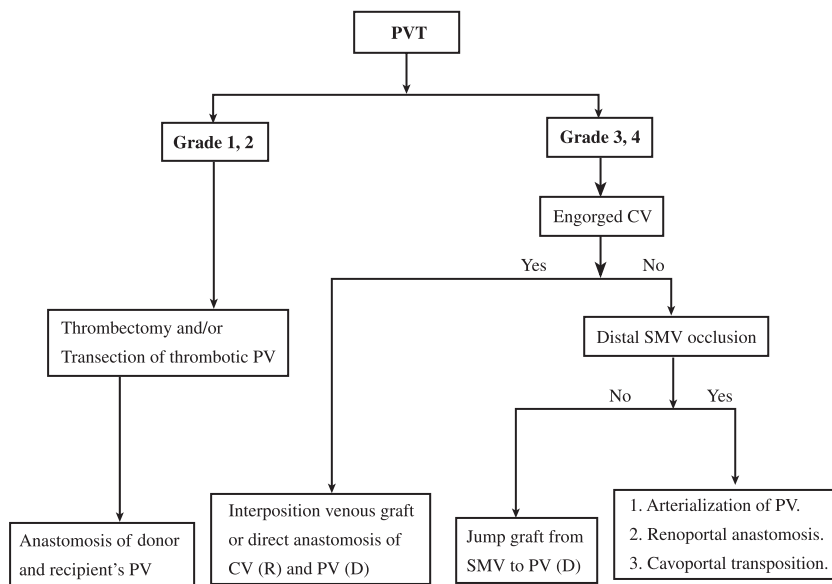


Fig. 3 Proposed strategy for the management of portal vein thrombosis during liver transplantation. Abbreviations used: PVT: portal vein thrombosis; PV: portal vein; CV: coronary vein; SMV: superior mesenteric vein; R: recipient; D: donor.

my with direct PV anastomosis is indicated in cases presenting with a mild degree of PVT. A more challenging technique and careful surgical management might be necessary in cases of total occlusion of the portal vein, such as with Yerdel grades 3 and 4. Generally, as long as adequate portal flow can be obtained, a simple procedure should be attempted when possible to prevent surgical complications. As our data shows, if the recipient's collateral CV is sufficiently large or engorged, the CV can be used to restore portal flow. A jump venous graft from the SMV is only indicated for the restoration of portal flow in cases of extensive PVT, and if there is no suitable engorged collateral CV available.

Although the current study was limited by the small number of patients included, several remarkable results have demonstrated that LT can be performed with favorable outcomes in recipients with PVT. Moreover, to ensure successful transplantation in patients with PVT, preoperative evaluation and thorough planning, as well as the ideal management of thrombus during LT, are essential.

REFERENCES

1. Amitrano L, Guardascione MA, Brancaccio V, Margaglione M, Manguso F, Iannaccone L, Grandone E, Balzano A. Risk factors and clinical presentation of portal vein thrombosis in patients with liver cirrhosis. *J Hepatol* 2004;40:736-41.
2. Janssen HL, Wijnhoud A, Haagsma EB, van Uum SH, van Nieuwkerk CM, Adang RP, Chamuleau RA, van Hutton J, Vleggaar FP, Hansen BE, Rosendaal FR, van Hoek B. Extrahepatic portal vein thrombosis: aetiology and determinants of survival. *Gut* 2001;49:720-4.
3. Manzanet G, Sanjuan F, Orbis P, Lopez R, Moya A, Juan M, Vila J, Asensi J, Sendra P, Ruiz J, Prieto M, Mir J. Liver transplantation in patients with portal vein thrombosis. *Liver Transpl* 2001;7:125-31.
4. Okuda K, Ohnishi K, Kimura K, Matsutani S, Sumida M, Goto N, Musha H, Takashi M, Suzuki N, Shinagawa T. Incidence of portal vein thrombosis in liver cirrhosis. An angiographic study in 708 patients. *Gastroenterology* 1985;89:279-86.
5. Paskonis M, Jurgaitis J, Mehrabi A, Kashfi A, Fonouni H, Strupas K, Buchler MW, Kraus TW. Surgical strategies for liver transplantation in the case of portal vein thrombosis--current role of cavoportal hemitransposition and renoportal anastomosis. *Clin Transplant* 2006;20:551-62.
6. Yerdel MA, Gunson B, Mirza D, Karayalcin K, Olliff S, Buckels J, Mayer D, McMaster P, Pirenne J. Portal vein thrombosis in adults undergoing liver transplantation: risk factors, screening, management, and outcome. *Transplantation* 2000;69:1873-81.
7. Lee KW, Lee DS, Lee HH, Joh JW, Choi SH, Heo JS, Lee SK, Kim SJ. Interposition vein graft in living donor liver transplantation. *Transplant Proc* 2004;36:2261-2.
8. Sugawara Y, Makuuchi M, Tamura S, Matsui Y, Kaneko J, Hasegawa K, Imamura H, Kokudo N, Motomura N, Takamoto S. Portal vein reconstruction in adult living donor liver transplantation using cryopreserved vein grafts. *Liver Transpl* 2006;12:1233-6.
9. Wu TH, Chou HS, Pan KT, Lee CS, Wu TJ, Chu SY, Chen MF, Lee WC. Application of cryopreserved vein grafts as a conduit between the coronary vein and liver graft to reconstruct portal flow in adult living liver transplantation. *Clin Transplant* 2009;23:751-5.
10. Egawa H, Tanaka K, Kasahara M, Takada Y, Oike F, Ogawa K, Sakamoto S, Kozaki K, Taira K, Ito T. Single center experience of 39 patients with preoperative portal vein thrombosis among 404 adult living donor liver transplantations. *Liver Transpl* 2006;12:1512-8.
11. Molmenti EP, Roodhouse TW, Molmenti H, Jaiswal K, Jung G, Marubashi S, Sanchez EQ, Gogel B, Levy MF, Goldstein RM, Fasola CG, Elliott EE, Bursac N, Mulligan D, Gonwa TA, Klintmalm GB. Thrombendvenectomy for organized portal vein thrombosis at the time of liver transplantation. *Ann Surg* 2002;235:292-6.
12. Tao YF, Teng F, Wang ZX, Guo WY, Shi XM, Wang GH, Ding GS, Fu ZR. Liver transplant recipients with portal vein thrombosis: a single center retrospective study. *Hepatobiliary Pancreat Dis Int* 2009;8:34-9.
13. Stieber AC, Zetti G, Todo S, Tzakis AG, Fung JJ, Marino I, Casavilla A, Selby RR, Starzl TE. The spectrum of portal vein thrombosis in liver transplantation. *Ann Surg* 1991;13:199-206.
14. Belli L, Romani F, Sansalone CV, Aseni P, Rondinara G. Portal thrombosis in cirrhotics. A retrospective analysis. *Ann Surg* 1986;203:286-91.
15. Sarfeh IJ. Portal vein thrombosis associated with cirrhosis: clinical importance. *Arch Surg* 1979;114:902-5.
16. Davidson BR, Gibson M, Dick R, Burroughs A, Rolles K. Incidence, risk factors, management, and outcome of portal vein abnormalities at orthotopic liver transplantation. *Transplantation* 1994;57:1174-7.
17. Englesbe MJ, Kubus J, Muhammad W, Sonnenday CJ, Welling T, Punch JD, Lynch RJ, Marrero JA, Pelletier SJ. Portal vein thrombosis and survival in patients with cirrhosis. *Liver Transpl* 2010;16:83-90.
18. Charco R, Fuster J, Fondevila C, Ferrer J, Mans E, Garcia-Valdecasas JC. Portal vein thrombosis in liver transplantation. *Transplant Proc* 2005;37:3904-5.
19. Seu P, Shackleton CR, Shaked A, Imagawa DK, Olthoff KM, Rudich SR, Kinkhabwala M, Busuttill RW. Improved results of liver transplantation in patients with portal vein thrombosis. *Arch Surg* 1996;131:840-4.
20. Orlando G, De LL, Toti L, Zazza S, Angelico M, Casciani

- CU, Tisone G. Liver transplantation in the presence of portal vein thrombosis: report from a single center. *Transplant Proc* 2004;36:199-202.
21. Nikitin D, Jennings LW, Khan T, Vasani S, Ruiz R, Sanchez EQ, Chinnakotla S, Levy MF, Goldstein RM, Klintmalm GB. Twenty years' follow-up of portal vein conduits in liver transplantation. *Liver Transpl* 2009;15:400-6.
22. Jia YP, Lu Q, Gong S, Ma BY, Wen XR, Peng YL, Lin L, Chen HY, Qiu L, Luo Y. Postoperative complications in patients with portal vein thrombosis after liver transplantation: evaluation with Doppler ultrasonography. *World J Gastroenterol* 2007;13:4636-40.

肝門靜脈栓塞的病患接受肝臟移植的臨床分析與策略

吳宗翰^{1,2} 林晏甥¹ 李正方^{1,2} 吳庭榕^{1,2} 游明晉¹ 詹昆明^{1,2} 李威震^{1,2}

- 背景：** 雖然肝臟移植對有肝門靜脈栓塞的病患已不再是絕對的禁忌症，但對移植外科醫生而言仍然是一個挑戰。在此，我們整理對於有肝門靜脈栓塞的病患接受肝臟移植的經驗及術後結果之分析。
- 方法：** 自 1996 年 9 月至 2009 年 6 月期間總共有 356 位病患於林口長庚紀念醫院接受肝臟移植，其中包括 167 例屍體捐肝移植和 189 例的活體捐肝移植，這當中有 24 位病患 (6.7%) 於肝臟移植時有肝門靜脈栓塞。針對這些病患的臨床特點，手術治療和結果進行回溯性的分析。
- 結果：** 此 24 例肝門靜脈栓塞的外科處理包括 13 例直接摘除血栓再行肝門靜脈吻合，3 例利用冰凍保存之大體捐贈的血管連接肝移植受贈者的冠狀靜脈和捐贈肝臟之肝門靜脈，1 例直接吻合受贈者之冠狀靜脈和肝臟之肝門靜脈，4 例利用冷藏之血管連接受贈者之上腸系膜靜脈和肝臟之肝門靜脈，3 例於截斷栓塞之門靜脈後利用冷藏之血管連接吻合捐贈者與受贈者的肝門靜脈。除了 7 位病患於術後住院期間死亡之外，其餘出院病患之平均追蹤期限為 36.4 個月，當中有 14 位病患目前仍然存活。有 4 位病患 (16.7%) 發生肝門靜脈再栓塞之情形。肝門靜脈栓塞的患者接受肝臟移植與沒有肝門靜脈栓塞的患者接受肝臟移植相比，有肝門靜脈栓塞的患者接受肝臟移植的手術死亡率相對較高 ($p = 0.033$)，但長期存活率並無統計上的顯著性差異 ($p = 0.0696$)。進一步的分析病患存活率根據肝門靜脈栓塞的程度及重建肝門靜脈的方式也顯示無統計上的顯著性差異。
- 結論：** 肝臟移植對有肝門靜脈栓塞的病患在臨床上是可行的，不應被視為肝臟移植的禁忌。但是於肝臟移植時必須要有理想的手術處理方式克服肝門靜脈栓塞，方可達到有利的結果。
(長庚醫誌 2011;34:426-34)

關鍵詞： 肝門靜脈栓塞，肝臟移植，手術處理，預後

長庚醫療財團法人林口長庚紀念醫院 ¹一般外科，²器官移植中心；長庚大學 醫學院

受文日期：民國99年8月24日；接受刊載：民國99年12月31日

通訊作者：詹昆明醫師，長庚醫療財團法人林口長庚紀念醫院 器官移植中心。桃園縣333龜山鄉復興街5號。

Tel.: (03)3281200轉3366; Fax: (03)3285818; E-mail: chankunming@cgmh.org.tw