

## Complications of Hip Fractures in Children

Feng-Chih Kuo<sup>1</sup>, MD; Shu-Jui Kuo<sup>1</sup>, MD; Jih-Yang Ko<sup>1,2</sup>, MD; To Wong<sup>1,2</sup>, MD

**Background:** Hip fractures account for < 1% of all pediatric fractures. Most are caused by a high-energy mechanism. Complications occur at a high rate because the vascular and osseous anatomy of the child's proximal femur is vulnerable to injury. The purposes of this study were to evaluate whether osteonecrosis influences the functional results and to analyze the risk factors for the development of osteonecrosis.

**Methods:** We conducted a retrospective review of the complications of hip fractures (3 transepiphyseal fractures, 13 transcervical fractures, 6 cervico-trochanteric fractures, and 1 intertrochanteric fracture) in 23 patients (15 boys and 8 girls) between January 1988 and December 1997. Most injuries were caused by falling from a height or a motorcycle accident. The medical records and serial radiographs of all patients were reviewed. The function of the injured site was evaluated using Ratliff's criteria.

**Results:** The ages of these children at the time of injury ranged from 1.5 to 16 years (average 11.1 years). The mean follow-up was 4.91 years (range, 1 year to 12 years and 7 months). Overall, complications included osteonecrosis in 11 (48%) patients, premature physeal closure in 11 (48%), coxa vara in 3 (13%) and coxa valga in 2 (9%). There was no nonunion. Poor outcomes were related to the development of osteonecrosis. The time to surgery ( $\leq 12$  hours) and the quality of reduction significantly influenced the occurrence of osteonecrosis. The occurrence and severity of femoral head osteonecrosis significantly influenced the functional results ( $p < 0.001$ , and  $p < 0.048$ , respectively).

**Conclusion:** Osteonecrosis is the most severe complication after hip fractures in children and is associated with poor functional results. The time to surgery and the quality of reduction were the significant predictors in our study.

(*Chang Gung Med J 2011;34:512-9*)

**Key words:** pediatric, hip fracture, complication, osteonecrosis

Fractures of the hip are rare in children and account for less than 1% of all pediatric fractures.<sup>(1)</sup> In contrast to adult hip fractures, pediatric and adolescent hip fractures are usually the result of high-energy trauma, because severe trauma is needed

to fracture the tough, dense bone of a child with its thick, strong periosteum.<sup>(2,3)</sup> Serious complications of hip fractures include osteonecrosis, nonunion, premature physeal closure, leg-length discrepancy, coxa vara, coxa valga and coxa magna.<sup>(3-8)</sup> Of these,

From the <sup>1</sup>Department of Orthopaedic Surgery Kaohsiung, Chang Gung Memorial Hospital and Chang Gung University College of Medicine, Kaohsiung, Taiwan; <sup>2</sup>Graduate Institute of Clinical Medical Science, Chang Gung University, Taoyuan, Taiwan.

Received: Aug. 4, 2010; Accepted: Feb. 21, 2011

Correspondence to: Dr. Jih-Yang Ko, Department of Orthopaedic Surgery, Kaohsiung Chang Gung Memorial Hospital, 123, Dapi Rd., Niasong District, Kaohsiung City 833, Taiwan (R.O.C.) Tel: 886-7-7317123 ext. 8003; Fax: 886-7-7354309;

E-mail: kojy@cgmh.org.tw

osteonecrosis is the leading cause of poor results as little can be done to salvage the affected hip.<sup>(1,9-11)</sup> Therefore, the best treatment is aimed at preventing osteonecrosis.

In recent studies, fracture type, displacement, age, treatment, and time to surgery have frequently been cited as risk factors for the development of osteonecrosis.<sup>(4,9,10,12-17)</sup> The purposes of this study were to evaluate whether osteonecrosis influences the functional results and to analyze the risk factors for development of osteonecrosis.

## METHODS

Between January 1988 and December 1997, 23 patients with pediatric hip fractures were treated at our institution. There were 15 boys and 8 girls. The mean age of the patients at fracture was 11.1 years (range, 1.5 to 16 years). Sixteen patients had left hip involvement, and 7 had right hip involvement. The mechanisms of injury included falling from a height in 12 patients (52%), motorcycle accidents in 5 (22%), bicycle accidents in 2, and a car accident, pedestrian-vehicle accident, basketball injury and rope skipping injury in one each. Using Delbert's classification, 3 patients had type I (transepiphyseal) fractures, 13 (57%) had type II (transcervical) fractures, 6 (26%) had type III (cervicotrochanteric) fractures and 1 had a type IV (intertrochanteric) fracture.

Buck's traction (2 kilograms) was applied for 3~5 days in patients with type IV and nondisplaced type III fractures. Then, closed reduction was performed and a hip spica cast was used until the fracture healed. In patients with type I, type II and displaced type III fractures, closed reduction and internal fixation with smooth pins, Knowles' pins, or cancellous screws were used. If the patient was under 10

years old or the fixation was not rigid enough, a hip spica was applied for postoperative protection. Open reduction and internal fixation were performed if closed reduction failed to achieve anatomical reduction under fluoroscopic guidance. Anatomical reduction was defined as < 2 mm of displacement and < 5° of angulation.<sup>(18)</sup> Capsular decompression was not used in fractures treated by closed reduction, but was performed when open reduction was indicated.

Medical record data of all patients including age, gender, method of operation, bony union, threaded pin penetration, time to removal of implant, and complications (osteonecrosis, nonunion, premature physeal closure, coxa vara, coxa valga, and shortening), were reviewed. The functional results and radiographic evaluations were assessed by the first author. The functional results were assessed as good, fair or poor based on the Ratliff criteria (Table 1).<sup>(1)</sup> These criteria included 4 items (pain, movement, activity, radiographic findings) used to assess functional results after femoral neck fractures in children. Ratliff<sup>(1)</sup> laid particular emphasis on the radiographic appearance, in the belief that this gave a good indication of the ultimate prognosis. If the radiographic grading was good, but more than two of the other parameters were rated fair or poor, we graded the result fair or poor. If the radiographic grading was fair or poor, but the other two or three parameters were rated good, the result was still rated fair or poor.

Nonunion was defined as failure of fixation with implant breakage, loss of reduction, or persistence of a visible fracture line at a minimum of 6 months after the index procedure.<sup>(18)</sup>

Using radiography, coxa vara was defined as a neck-shaft angle of less than 120 degrees and coxa valga was defined as a neck-shaft angle of more than

**Table 1.** Ratliff Criteria for Functional Assessment of the Results of Treatment for Fracture of the Hip

	Good	Fair	Poor
Pain	None or "ignores"	Occasional	Disabling
Movement	Full or terminal restriction	Greater than 50%	Less than 50%
Activity	Normal or avoids games	Normal or avoids games	Restricted
Radiographic findings	Normal or some deformity of the neck	Severe deformity of the femoral neck	Severe avascular necrosis, degenerative arthritis, arthrodesis

150 degrees.<sup>(14)</sup> Premature physeal closure was defined when 50% or more of the physis had a linear closure.<sup>(19)</sup> Shortening (leg-length discrepancy) was detected by using a standing scanogram. A significant leg-length discrepancy was defined as > 2 cm shortening.<sup>(20-22)</sup> Coxa brevis, a deformity of the proximal femur, is caused by decreased or absent growth of the proximal femoral physis.<sup>(23)</sup> The deformity is marked by a classic radiographic appearance of a short femoral neck. We described the reduction quality using a modification of the method of Haidukewych et al.<sup>(18)</sup> We defined anatomical (acceptable) reduction as < 2 mm of displacement and < 5° of angulation and non-anatomical reduction as ≥ 2 mm of displacement and/or > 5° of angulation.

We analyzed the factors related to osteonecrosis, including age, displacement, time to surgery (≤ 12 hours), capsular decompression and the quality of reduction. Statistical analysis was performed using Fisher's exact test, and *p* values ≤ 0.05 were considered statistically significant.

## RESULTS

One patient with a type I fracture underwent open reduction and internal fixation because of failure of closed reduction. The other 2 patients with type I fractures received closed reduction and internal fixation. Twelve patients with type II fractures underwent closed reduction and internal fixation. One patient with a type II fracture had open reduction because of failure of closed reduction. The 6 patients with type III fractures had closed reduction and internal fixation. The patient with a type IV fracture had closed reduction and hip spica immobilization. Bone union was obtained in all patients at a mean 11 weeks (range 4 weeks to 20 weeks) after

injury.

At a mean follow-up of 4.91 years (range, 1 year to 12 years 7 months), there were good results in 12 hips (52%), fair in 8 (35%), and poor in 3 (13%). One patient with a poor result had progressive coxa vara and underwent subtrochanteric valgus osteotomy 6 months after the initial operation. The other 2 patients with poor results had type I osteonecrosis, coxa brevis and coxa vara, and were managed with observation and nonsurgical treatment. Two patients underwent open reduction, and both had osteonecrosis during follow-up. The mean duration to removal of internal fixation was 12.7 months (range: 5 weeks to 2 years, 2 months).

Table 2 presents the overall complications. The osteonecrosis rate was 48% (11 of 23), and was noted in 2 patients with transepiphyseal fracture, 7 patients with transcervical fracture and 2 patients with cervicotrochanteric fracture (Fig. 1). Three patients had poor outcomes and 8 patients had fair outcomes. The other 12 patients without osteonecrosis had good results, which was statistically significant (*p* < 0.001). Ratliff type I osteonecrosis (involvement of the whole head) was noted in 4 patients, type II osteonecrosis (partial involvement of the head) in 2 and type III osteonecrosis (an area of necrosis from the fracture line to the physis) in 5. Among the 4 patients with Ratliff type I osteonecrosis, 3 had a poor outcomes and one had a fair outcome. The patients with Ratliff type II and type III osteonecrosis had fair outcomes, which was statistically significant (*p* = 0.048). Nonsurgical treatment and observation were used for these patients.

The rate of premature physeal closure was 47.8% (11 of 23) (Fig. 2). Coxa vara occurred in 3 (13%) patients, and coxa valga occurred in 1 (4%). Seven patients had leg-length discrepancy, and 2 of

**Table 2.** Complications among Different Types of Hip Fractures in Children

Fracture type	Osteonecrosis	Premature physeal closure	Nonunion	Coxa vara	Coxa valga	Shortening	Total
I (n = 3)	2	3	–	–	1	–	6
II (n = 13)	7	5	–	2	1	5	20
III (n = 6)	2	3	–	1	–	2	8
IV (n = 1)	–	–	–	–	–	–	0
Total (n = 23)	11	11	0	3	2	7	34

them had significant leg-length discrepancy (> 2 cm). There were no nonunion or infection complications in our study.

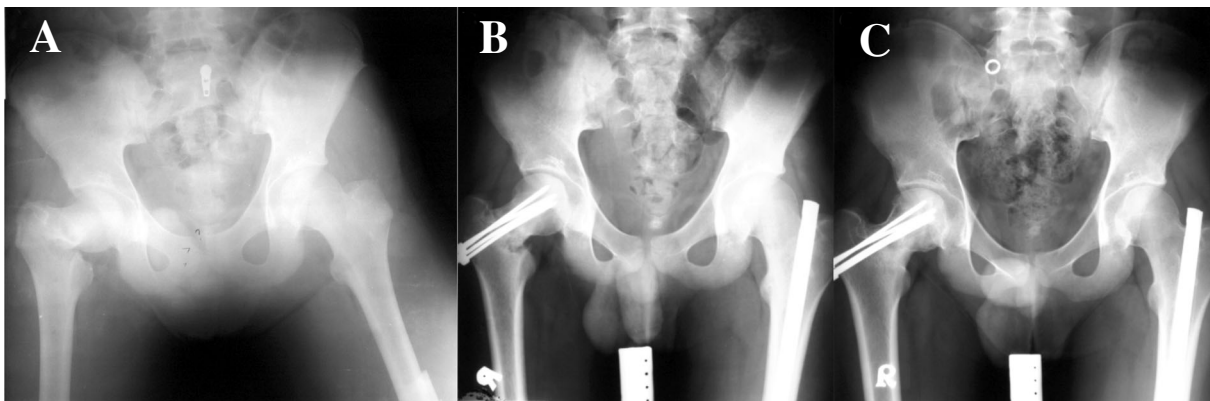
We analyzed the factors related to osteonecrosis and found only the time to surgery ( $\leq 12$  hours) and quality of reduction (anatomical reduction) had a significant effect on the risk of osteonecrosis (Table 3); other factors, including fracture type, did not. Premature physeal closure had a moderate correlation coefficient in relation to osteonecrosis, this but did not reach statistical significance.

## DISCUSSION

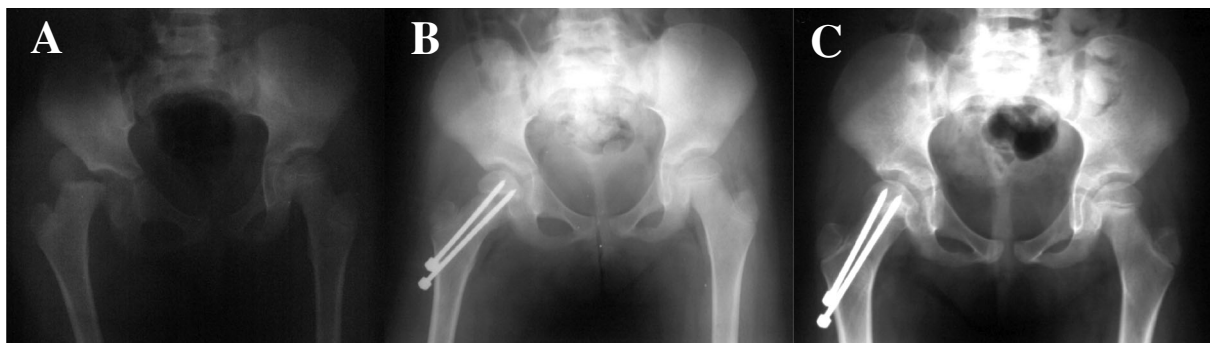Osteonecrosis is the most common complication following hip fractures in children.<sup>(13,16,24,25)</sup> Previous studies reported osteonecrosis rates of 10% to

58%.<sup>(1,4,16,25)</sup> Predicting osteonecrosis is of critical importance because of the poor results associated with its occurrence and the lack of treatment options once it is established.<sup>(25)</sup> In our study, 12 patients had no development of osteonecrosis and the results were good. On the other hand, of the 11 patients with osteonecrosis, 3 had poor results and 8 had fair results, which was statistically significant ( $p < 0.001$ ). Ratliff type I osteonecrosis was related to poor results more often than Ratliff type II or type III osteonecrosis ( $p = 0.048$ ).

In a meta-analysis of 360 pediatric hip fractures, Moon et al. demonstrated that fracture type and age at the time of injury were the best predictors of osteonecrosis.<sup>(25)</sup> Type I, II and III fractures were respectively 15, 6 and 4 times as likely to develop osteonecrosis than type IV fractures. However, in a



**Fig. 1** Right type III femoral neck fracture and left femoral shaft fracture in a 16-year-old boy. (A) Preoperative radiograph of a right cervicotrochanteric fracture and left femoral shaft fracture. (B) Closed reduction and fixation with 4 Knowles pins and a Kuntcher nails for each fracture. (C) Radiograph 1 year and 6 months after the operation showing osteonecrosis of the right femoral head.



**Fig. 2** Premature physeal closure after a type 1 femoral neck fracture. (A) Type 1 femoral neck fracture-dislocation in a 8-year-old boy. (B) Open reduction and internal fixation 3 days after injury. (C) Follow-up radiography after 6 months showing premature physeal closure.

**Table 3.** Predictive Risk Factors for Osteonecrosis

Parameters	Patient number	AVN number	<i>p</i> value
Age < 10 years	6	1	0.076
Age > 10 years	17	10	
Displaced	20	10	0.59
Non-displaced	3	1	
< 12 hours to surgery	11	2	0.022
> 12 hours to surgery	12	9	
Capsular decompression	2	2	0.112
No capsular decompression	21	9	
Anatomical reduction	16	5	0.016
Non-anatomical reduction	7	6	

**Abbreviation:** AVN: Avascular necrosis.

recently published study, Dendane et al. reported 21 children with displaced femoral neck fractures,<sup>(26)</sup> and found a higher rate of osteonecrosis in type II fractures (44.44%) than in type III fractures (20%), which was not statistically significant ( $p > 0.05$ ). In our study, the rate of femoral head osteonecrosis decreased as the hip fracture level decreased, from the epiphysis to the trochanteric area (Type I, 67%; Type II, 53.8%; Type III, 33.3%; type IV, 0%), but the tendency was not statistically significant. Types I-III showed higher rates of osteonecrosis than type IV fractures (0%). This may be because of the limited patient number. But we still believe that meticulous reduction of high level fractures may reduce the incidence of femoral head osteonecrosis.

In our study, patients under 10 years old had a 17% rate of osteonecrosis, whereas those over 10 years old had a 59% rate of osteonecrosis. A study by Kay et al. also observed a similar phenomenon with 6 of 9 cases of osteonecrosis occurring in children older than 10 years.<sup>(3)</sup> However, this was not shown in our study. These 2 factors (type of fracture and age at the time of injury) showed no statistically significant differences, probably because of the limited patient numbers.

Displacement of the femoral neck in childhood fractures is also a predictor of osteonecrosis.<sup>(1,2,4-6,27,28)</sup> Disruption of blood flow occurs at the time of injury. It may be caused by kinking of vessels occurring with the fracture displacement or by direct laceration

of blood vessels by fracture fragments. Tamponade of vessels supplying the proximal femur by increased intracapsular pressure is another potential cause of ischemia.<sup>(20)</sup> However, Kay et al. reported that displaced fractures,<sup>(3)</sup> with their sharp fragments, can rupture the capsule and release this pressure. Thus, displacement may have a protective effect by preventing the buildup of intraarticular pressure.<sup>(3)</sup> In our study, we did not observe a significant difference in the risk of osteonecrosis between displaced and non-displaced fractures or between capsular decompression and no capsular decompression during surgery. We cannot exclude a direct effect between the severity of the initial trauma and avascular necrosis.

Time to surgery is also a known predictor of osteonecrosis. Flynn et al. reported 18 patients who received early reduction and internal fixation and underwent long periods of non-weight-bearing.<sup>(21)</sup> The incidence of osteonecrosis was low (6%). Cheng et al. reported 14 patients who were treated by decompression and stable fixation with closed or open reduction within 24 hours of admission.<sup>(22)</sup> He reported no occurrence of osteonecrosis. One recently published study described delayed fixation of displaced type II and III pediatric femoral neck fractures in 22 patients.<sup>(29)</sup> The authors found osteonecrosis in 8 patients (36.3%), including 2 of 9 patients (22.22%) with operations in the first week after injury, 3 of 8 patients (37.51%) in the second week, and 3 of 5 patients (60%) in the third week. Another study included 21 children with displaced fractures in the femoral neck who were treated with delayed fixation (> 24 hours).<sup>(30)</sup> Three (14.3%) patients had osteonecrosis of the hip, which was significantly related to a poor outcome ( $p = 0.022$ ). There was a significant correlation ( $r = 0.52$ ) between the development of osteonecrosis and delayed fracture fixation of > 10 days ( $p = 0.016$ ). Shrader et al. found there was an association ( $p = 0.05$ ) between delayed treatment (> 24 hours) and osteonecrosis in 20 pediatric patients with femoral neck fractures.<sup>(31)</sup> In our study, we defined early reduction as  $\leq 12$  hours. Of 11 patients treated within 12 hours, only 2 patients developed osteonecrosis, which compared favorably with patients treated after 12 hours (9 out of the 12 patients had osteonecrosis,  $p = 0.022$ ). We suggest that early stable internal fixation of a pediatric femoral neck fracture may reduce the incidence of osteonecrosis.

The quality of reduction (anatomical reduction vs. non-anatomical reduction) was also a significant predictive factor ( $p = 0.016$ ) for osteonecrosis in our study. Five of the 16 cases with anatomical reduction and 6 of the 7 cases without anatomical reduction developed osteonecrosis ( $p = 0.016$ ). Morsy et al. reported osteonecrosis in 10 of 14 cases with non-anatomical reduction,<sup>(8)</sup> compared with only 4 of the 23 cases with anatomical reduction ( $p < 0.01$ ). Shrader et al. reported that no patient with an excellent or good final reduction developed osteonecrosis,<sup>(31)</sup> whereas the patients with fair or poor reductions developed osteonecrosis ( $p < 0.01$ ). Therefore, the surgeon should strive for an anatomical reduction in every case to decrease the development of osteonecrosis.

Premature physal closure after hip fractures has been reported with an incidence ranging from 5% to 65% of cases.<sup>(2,4,5,8,13,15,32)</sup> A significant correlation between osteonecrosis and premature physal closure was found in past studies.<sup>(8,12)</sup> This can be explained by the disruption to the blood supply of the growth plate, which may occur at the time of injury or by penetration of an internal device.<sup>(4,12,27)</sup> Since the capital femoral physis contributes 13% of overall limb length, complete physal closure in very young children may result in a significant ( $> 2$  cm) limb-length discrepancy. Children with premature physal closure should be followed with limb-length scanograms; if the limb length discrepancy is projected to be 2.5 cm or more, a scheduled contralateral epiphysiodesis can be performed.<sup>(20,33)</sup>

Coxa vara may be caused by malreduction (varus) of the fracture, loss of reduction, delayed union or nonunion, osteonecrosis, or premature closure of the proximal femoral physis with overgrowth of the greater trochanter.<sup>(2,4,5,8,32)</sup> Reports of coxa vara vary from 8% to 36% in children with hip fractures.<sup>(13,15,24)</sup> Remodeling may occur in very young children (approximately 0 to 3 years old) with mild coxa vara if the neck-shaft angle is  $> 110^\circ$ .<sup>(13,33)</sup> A subtrochanteric valgus osteotomy may be considered for children older than 8 years and for those with a neck-shaft angle of less than 110 degrees.<sup>(2)</sup>

The limitations of this study include the small patient number and the short follow-up. In addition, this was an observational, retrospective study, so the scientific analysis needs further evaluation.

## Conclusion

Osteonecrosis is the most severe complication after femoral neck fracture in children. It is associated with poor functional results. Early surgery and anatomical reduction could decrease the occurrence of osteonecrosis.

## REFERENCES

1. Ratliff AH. Fractures of the neck of the femur in children. *J Bone Joint Surg Br* 1962;44:528-42.
2. Hughes LO, Beatty JH. Fractures of the head and neck of the femur in children. *J Bone Joint Surg Am* 1994;76:283-92.
3. Kay SP, Hall JE. Fracture of the femoral neck in children and its complications. *Clin Orthop Relat Res* 1971;80:53-71.
4. Canale ST, Bourland WL. Fracture of the neck and intertrochanteric region of the femur in children. *J Bone Joint Surg Am* 1977;59:431-43.
5. Davison BL, Weinstein SL. Hip fractures in children: a long-term follow-up study. *J Pediatr Orthop* 1992;12:355-8.
6. Pape HC, Krettek C, Friedrich A, Pohlemann T, Simon R, Tscherne H. Long-term outcome in children with fractures of the proximal femur after high-energy trauma. *J Trauma* 1999;46:58-64.
7. Ovesen O, Arreskov J, Bellstrom T. Hip fractures in children. A long-term follow up of 17 cases. *Orthopedics* 1989;12:361-7.
8. Morsy HA. Complications of fracture of the neck of the femur in children. A long-term follow-up study. *Injury* 2001;32:45-51.
9. Forlin E, Guille JT, Kumar SJ, Rhee KJ. Complications associated with fracture of the neck of the femur in children. *J Pediatr Orthop* 1992;12:503-9.
10. Morrissy R. Hip fractures in children. *Clin Orthop Relat Res* 1980;152:202-10.
11. Kregor PJ. The effect of femoral neck fractures on femoral head blood flow. *Orthopedics* 1996;19:1031-6; quiz 1037-8.
12. Heiser JM, Oppenheim WL. Fractures of the hip in children: a review of forty cases. *Clin Orthop Relat Res* 1980;149:177-84.
13. Lam SF. Fractures of the neck of the femur in children. *J Bone Joint Surg Am* 1971;53:1165-79.
14. Bagatur AE, Zorer G. Complications associated with surgically treated hip fractures in children. *J Pediatr Orthop B* 2002;11:219-28.
15. Pforringer W, Rosemeyer B. Fractures of the hip in children and adolescents. *Acta Orthop Scand* 1980;51:91-108.
16. Swiontkowski MF, Winquist RA. Displaced hip fractures in children and adolescents. *J Trauma* 1986;26:384-8.
17. Weiner DS, O'Dell HW. Fractures of the hip in children. *J*

- Trauma 1969;9:62-76.
18. Haidukewych GJ, Rothwell WS, Jacofsky DJ, Torchia ME, Berry DJ. Operative treatment of femoral neck fractures in patients between the ages of fifteen and fifty years. *J Bone Joint Surg Am* 2004;86:1711-6.
  19. Chen CE, Ko JY, Wang CJ. Premature closure of the physal plate after traumatic or slipped capital femoral epiphysis. *Chang Gung Med J* 2002;25:811-8.
  20. Boardman MJ, Herman MJ, Buck B, Pizzutillo PD. Hip fractures in children. *J Am Acad Orthop Surg* 2009;17:162-73.
  21. Flynn JM, Wong KL, Yeh GL, Meyer JS, Davidson RS. Displaced fractures of the hip in children. Management by early operation and immobilisation in a hip spica cast. *J Bone Joint Surg Br* 2002;84:108-12.
  22. Cheng JC, Tang N. Decompression and stable internal fixation of femoral neck fractures in children can affect the outcome. *J Pediatr Orthop* 1999;19:338-43.
  23. Eilert RE, Hill K, Bach J. Greater trochanteric transfer for the treatment of coxa brevis. *Clin Orthop Relat Res* 2005;434:92-101.
  24. Togrul E, Bayram H, Gulsen M, Kalaci A, Ozbarlas S. Fractures of the femoral neck in children: long-term follow-up in 62 hip fractures. *Injury* 2005;36:123-30.
  25. Moon ES, Mehlman CT. Risk factors for avascular necrosis after femoral neck fractures in children: 25 Cincinnati cases and meta-analysis of 360 cases. *J Orthop Trauma* 2006;20:323-9.
  26. Dendane MA, Amrani A, El Alami ZF, El Medhi T, Gourinda H. Displaced femoral neck fractures in children: are complications predictable? *Orthop Traumatol Surg Res* 2010;96:161-5.
  27. Ingram AJ, Bachynski B. Fractures of the hip in children; treatment and results. *J Bone Joint Surg Am* 1953;35-A:867-87.
  28. Leung PC, Lam SF. Long-term follow-up of children with femoral neck fractures. *J Bone Joint Surg Br* 1986;68:537-40.
  29. Azam MQ, Iraqi A, Sherwani M, Abbas M, Alam A, Sabir AB, Asif N. Delayed fixation of displaced type II and III pediatric femoral neck fractures. *Indian J Orthop* 2009;43:253-8.
  30. Varshney MK, Kumar A, Khan SA, Rastogi S. Functional and radiological outcome after delayed fixation of femoral neck fractures in pediatric patients. *J Orthop Traumatol* 2009;10:211-6.
  31. Shrader MW, Jacofsky DJ, Stans AA, Shaughnessy WJ, Haidukewych GJ. Femoral neck fractures in pediatric patients: 30 years experience at a level I trauma center. *Clin Orthop Relat Res* 2007;454:169-73.
  32. Azouz EM, Karamitsos C, Reed MH, Baker L, Kozlowski K, Hoeffel JC. Types and complications of femoral neck fractures in children. *Pediatr Radiol* 1993;23:415-20.
  33. Beaty JH. Fractures of the hip in children. *Orthop Clin North Am* 2006;37:223-32.

## 兒童股骨頸骨折之併發症

郭峯志<sup>1</sup> 郭書瑞<sup>1</sup> 郭繼陽<sup>1,2</sup> 黃濤<sup>1,2</sup>

- 背景：** 髖部骨折約佔了所有兒童骨折不到 1%。大部份的骨折是因高能量的受傷機制引起。兒童近端股骨因血管及骨頭解剖構造的關係，導致併發症的機率偏高。
- 方法：** 在 1988 年 1 月至 1997 年 12 月，此回溯性研究收集了 23 個病人 (15 個男孩，8 個女孩) 有股骨頸骨折。大部份的受傷機制為跌落或車禍。所有的病人都分析其病歷，X 光片及評估患肢功能。
- 結果：** 受傷的年紀是 1.5 歲到 16 歲 (平均 11.1 歲)。平均追蹤的時間為 4.91 年。發生的併發症包括，11 個股骨頭壞死 (48%)，3 個髖內翻 (13%)，11 個生長板提早閉合 (48%)，2 個髖外翻 (9%)。此外沒有任何病人有未癒合等併發症。病人的不良預後跟產生股骨頭壞死有相關。受傷到接受手術的時間和骨折復位的品質影響了日後產生股骨頭壞死的可能。
- 結論：** 股骨頭壞死為兒童髖部骨折最常見的併發症，且跟不良預後功能有關係。受傷到接受手術的時間及骨折復位的品質則是在我們的研究中為有統計意義的預測因子。  
(長庚醫誌 2011;34:512-9)

**關鍵詞：** 兒童，髖部骨折，併發症，股骨頭壞死

---

<sup>1</sup>長庚醫療財團法人高雄長庚紀念醫院 骨科系；長庚大學 醫學院 臨床醫學研究所

受文日期：民國99年8月4日；接受刊載：民國100年2月21日

通訊作者：郭繼陽醫師，長庚醫療財團法人高雄長庚紀念醫院 骨科系。高雄市833鳥松區大埤路123號。

Tel: (07)7317123轉8003; Fax: (07)7354309; E-mail: kojy@cgmh.org.tw