

## Survivin Expression in Cardiac Myxoma

Yu-Sheng Lin, MD; Shih-Ming Jung<sup>1</sup>, MD; Hsueh-Hwa Wu<sup>2</sup>; Tzu-Fang Shiu<sup>2</sup>;  
Feng-Chun Tzai<sup>3</sup>, MD; Jaw-Ji Chu<sup>3</sup>, MD; Pyng-Jing Lin<sup>3</sup>, MD; Pao-Hsien Chu<sup>2</sup>, MD

**Background:** Cardiac myxoma, the most common primary tumor of the heart, has variable clinical presentations and an immunohistochemical profile. Survivin, an anti-apoptosis protein, may play an important role in the causes of cardiac myxoma. This investigation will report the expression pattern of survivin in cardiac myxomas.

**Methods:** This study included 40 patients with cardiac myxoma, who were treated with surgical excision of the lesion. Detailed clinical parameters were reported and the expression of survivin was studied by immunohistochemical staining.

**Results:** The patient population was comprised of 24 (60%) women and 16 (40%) men. The mean age of the patients was 42 years, with an age range of 30 to 63 years. All study cases were sporadic myxomas rather than familial myxoma. Patients were asymptomatic (20%), or had dyspnea (40%), stroke (15%), chest pain (12%), and fever (12%) on presentation. All lesions were located in the left atrium. The location of the myxoma and clinical events did not differ in terms of pathological changes, such as vascular proliferation, inflammation, cellularity, hyaline, calcification and thrombosis. Cardiac myxoma was characterized by a survivin dependent pathway with 100% immunohistochemical staining in the cytoplasm and the distribution in scoring system of survivin expression were 1 case (2.5%) in score 1; 12 cases (30%) in score 2; 12 cases (30%) in score 3 and 15 (37.5%) in score 4.

**Conclusion:** Cardiac myxomas demonstrate strong expression of survivin in the cytoplasm. This implies survivin may play an important role in the apoptosis pathway in cardiac myxomas.  
(*Chang Gung Med J 2011;34:360-6*)

**Key words:** apoptosis, cardiac myxoma, survivin

Survivin has been identified as a new member of the inhibitor of apoptosis protein (IAP) family, and is characterized by a unique structure that discriminates it from all other members of the IAP family.<sup>(1)</sup> It contains only a single baculovirus IAP repeat and lacks a carboxy terminal RING finger domain.<sup>(2)</sup>

It is expressed in the G2/M phase of the cell cycle in a cycle-regulated manner and directly binds to and inhibits both caspase-3 and caspase-7 activity leading to arrest of apoptosis.<sup>(3)</sup> In clinical implications, survivin expression is not detectable in differentiated normal adult cells of any organ but it is highly

---

From the Division of Cardiology, Chang Gung Memorial Hospital at Chiayi; <sup>1</sup>Department of Pathology; <sup>2</sup>Division of Cardiology; <sup>3</sup>Division of Thoracic & Cardiovascular Surgery, Chang Gung Memorial Hospital at Linkou, Chang Gung University College of Medicine, Taoyuan, Taiwan.

Received: July 8, 2010; Accepted: Jan. 5, 2011

Correspondence to: Dr. Pao-Hsien Chu, Division of Cardiology, Chang Gung Memorial Hospital at Linkou, 5, Fusing St., Gueishan Township, Taoyuan County 333, Taiwan (R.O.C.) Tel.: 886-3-3281200 ext. 8162; Fax: 886-3-3271192; E-mail: pchu@cgmh.org.tw

expressed in a wide range of cancer tissues including breast,<sup>(4)</sup> colorectal,<sup>(5-7)</sup> gastric,<sup>(8)</sup> and prostate cancer,<sup>(9)</sup> and melanoma,<sup>(10)</sup> as well as hematopoietic malignancies.<sup>(2,11)</sup> Owing to the potent caspase-inhibitor, its expression in cancer cells implicates it in resistance to different apoptotic stimuli including chemotherapy.<sup>(12)</sup> Therefore, survivin plays an essential dual role in cell division and as an inhibitor of apoptosis.<sup>(13)</sup>

Apoptosis is well known to associate with the prognosis of heart disease, including ischemic heart disease, cardiomyopathy<sup>(14)</sup> and even myxoma,<sup>(15-17)</sup> which is the most common neoplasm of heart leading to or severe complications.<sup>(18-21)</sup> Although one study speculated embolic events might relate to apoptosis,<sup>(16)</sup> it did not exactly correlate with clinical or pathologic changes in our previous study.<sup>(15)</sup> Further, because of the potential clinical benefits of survivin-directed therapeutics, extensive efforts have been devoted to understand how survivin becomes so sharply differentially expressed in tumors, such as cardiac myxomas, compared to most normal tissues. Therefore, it is important to elucidate the expression patterns of survivin and apoptosis in cardiac myxomas.

## METHODS

Samples of cardiac myxoma were obtained from patients who had surgical excision at the Chang Gung Memorial Hospital, Taiwan. All patients provided informed consent for the study procedures, which were reviewed and approved by the Institutional Review Board of Chang Gung Memorial Hospital (96-0610B). The study conformed to the tenets of the Declaration of Helsinki. Detailed clinical parameters were also obtained at this time. Information on age, sex, presenting symptoms, echocardiographic characteristics, and surgical procedures were obtained from patient medical records. Follow-up data were gathered from clinical records and from standardized telephone interviews. The tumor size and morphologic features for each patient were retrieved from surgical pathology reports. All sections were stained with hematoxylin-eosin and examined for vascular proliferation, inflammation, cellularity, hyaline, calcification, thrombosis, fibrosis, and Gamna-Gandy bodies. The clinical and pathologic features of the cardiac myxomas were assessed statistically to identify morpho-

logical features related to embolism, atrial fibrillation, and patient age at diagnosis. Echocardiographic features also were compared using the same pathologic findings.

### Immunohistochemical stain for *Survivin*

The survivin (1:50; H-277; Santa Cruz Biotechnology, Inc., Santa Cruz, CA, U.S.A.) assay was used per manufacturer protocol. Sections stained with phosphate-buffered saline substituted for the primary antibody were used for negative controls; breast cancer sections were used for positive controls.

The proportion of cells per 100 cardiac myxoma cells showing terminal deoxynucleotidyl transferase dUTP nick end labeling (TUNEL) and survivin positivity were scored as follows: (A) 0, < 5% positive cells; (B) 1, 5-25%; (C) 2, 25-50%; (D) 3, 50-75%; (E) 4, > 75%. Sections with < 5% positively staining cells were defined as survivin-negative; all others were defined as survivin-positive. Statistical analysis Continuous variables were described as means  $\pm$  SD or median (interquartile range). Categorical variables were presented as number or percentages. Continuous variables were compared by Student *t* test (two-tailed) for parametric data. Categorical variables between the proportion groups were compared using the chi-square test. Statistical analysis was performed using SPSS 15 statistical software for Windows (SPSS Inc, Chicago, IL, U.S.A.). All *p* values were two-sided, and the level of statistical significance was set at 0.05.

## RESULTS

### Clinical findings

The patient population was comprised of 24 (60%) women and 16 (40%) men, with a mean age of 42 years, ranging in age from 30 to 63 years. All patients had sporadic myxomas rather than familial myxoma.<sup>(15,26,27)</sup> Patients were asymptomatic (20%), or had dyspnea (40%), stroke (15%), chest pain (12%), and fever (12%) on initial presentation. All cardiac myxoma tumors were confined to the left atrium. Tumors ranged in weight from 5 to 54 g (mean 30.2 g). No patients experienced atrial fibrillation prior to or during the study. All chest radiographs displayed nonspecific changes. All patients were mildly anemic, with an average hemoglobin of 10.4 mg/dL.

Most patients experienced mild mitral valve and tricuspid valve regurgitation. No perioperative mortality or embolization occurred. All patients were surviving at the time of this writing. The mean time from patient treatment to the time of this writing was nine months, with a range of 1 to 3 years. None of the patients enrolled in the study had metastases or recurrence of disease. Preoperative diagnosis was made by use of transthoracic echocardiography.

### Pathologic findings

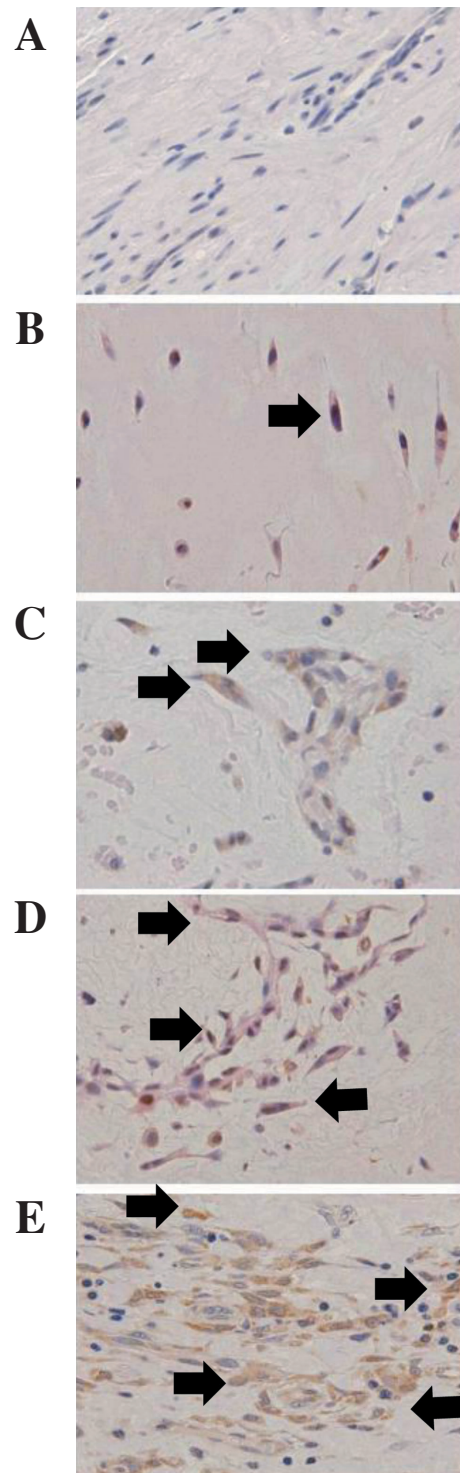
Microscopic examination revealed high levels of vascular proliferation (85%), hyaline formation (80%), congestive areas (80%), inflammation (50%), and multiple giant cells (40%) in the patients. Hemorrhagic foci (10%) and calcification (10%) were noted occasionally. There were no cases of cardiac lithomyxoma in this study.

### Expression of survivin in cardiac myxomas

All immunochemical studies of survivin were positive in both the cytoplasm and cell membrane (Fig. 1, arrowhead). Survivin was expressed in 100% of the cytoplasm and 2.5% of the nuclei. The distribution in scoring system of survivin expression in the cytoplasm were 1 case (2.5%) in score 1; 12 cases (30%) in score 2 (one of which was combined with score 2 survivin expression in nuclei), 12 cases (30%) in score 3, and 15 cases (37.5%) in score 4. In the subgroup analysis for clinical presentations and pathological findings in different scoring group, there were no significant differences can be found (Tables 1 and 2).

## DISCUSSION

Myxoma is the most common neoplasm among cardiac tumors. In this study, the clinical presentations as well as pathologic features, such as vascular proliferation, hyaline formation, congestive areas, inflammation, hemorrhagic foci, calcification, and percentage of giant cells, were similar to previous studies.<sup>(15,18-22)</sup> Although the characteristics of a myxoma, such as the well differentiated cell components, very slow progression in size and rare metastasis, are similar to those of a benign tumor, it sometimes deemed malignant because of embolic events and recurrence, especially in familial myxoma.<sup>(18)</sup> Therefore, research has been directed towards identi-



**Fig. 1** Representative pictures showing typical survivin staining in cardiac myxoma (black arrowhead. X400 in original magnification). (A) score of 0, < 5% positive cells; (B) 1, 5-25%; (C) 2, 25-50%; (D) 3, 50-75%; (E) 4, > 75%.

**Table 1.** Clinical Presentations with Different Levels of Expression of Survivin

	Expression of survivin	Score 1	Score 2	Score 3	Score 4
	Numbers	1	12	12	15
Clinical presentations	Asymptomatic	0	3	1	4
	Dyspnea	1	5	5	5
	Stroke	0	2	3	1
	Chest pain	0	1	2	3
	fever	0	1	2	3

**Table 2.** Pathologic Changes with Different Levels of Expression of Survivin

	Expression of survivin	Score 1	Score 2	Score 3	Score 4
	Numbers	1	12	12	15
Pathologic findings	Vascular proliferation	0	12	11	11
	Hyaline formation	1	10	9	12
	Congestive areas	0	11	11	10
	Inflammation	1	4	7	8
	Multiple giant cells	0	6	5	5
	Hemorrhagic foci	1	1	2	0
	Calcification	1	1	1	1

fyng specific histopathological changes,<sup>(18,20)</sup> biomarkers,<sup>(23-25)</sup> and gene expression<sup>(26,27)</sup> in myxomas to correlate to such clinical presentations, but in vain. In recent years, research has been directed to studying apoptosis in cardiac myxomas.<sup>(15,17)</sup> To the best of our knowledge, there is no study on the expression of survivin in myxoma.

In this study, survivin was expressed in the cytoplasm of all myxomas, but in only 2.5% of the nuclei. The cytoplasmic survivin expression corresponds with previous studies of survivin expression in other malignant cells,<sup>(1)</sup> and can be explained by the anti-apoptosis effect of survivin, as it inhibits both caspase-3 and caspase-7 activity. In the conclusion of this study and highly expressing of apoptosis in myxoma reported in previous study.<sup>(15)</sup> The high activity of survivin in apoptosis process in myxoma would be reasonable speculated. Therefore, the high survivin expression in cardiac myxoma might provide directions for further research of the pathophysiology of cardiac myxomas. First, it may provide a hints to investigate the mechanism of the apoptosis

process in myxomas, because survivin expression is well correlated with apoptosis expression in this tumor. Second, surgical removal would not be the only choice in myxoma, and anti-survivin target therapy could be used. Many studies have indicated that survivin plays an important role in tumorigenesis and virus infection-induced carcinogenesis<sup>(12)</sup> and it has been well correlated with chemotherapy/ radiotherapy resistance in some cancers.<sup>(12,13)</sup> Therefore, it is possible that it may be a further target therapy for cancer in the future under the theory of increasing the rate of apoptosis and then suppressing tumorigenesis by suppressing the function of survivin. Further study could determine whether anti-survivin agents can attenuate the survival of myxoma cell lines. Third, survivin has been correlated with recurrence in selected cancers,<sup>(12,13)</sup> and might be a possibility in the recurrence of myxoma. Although there is a low incidence of recurrence in sporadic myxoma, the recurrence rate in familial and complex myxoma is as high as 12~22%.<sup>(19)</sup> In addition, although recurrence was mostly related to incomplete resection,



intraoperative displacement of tumor material, and embolization in previous study, the role of immunohistologic changes and gene expression have never been investigated.<sup>(19)</sup> Therefore, correlation between survivin expression and recurrence should be further investigated.

This investigation has several limitations. First, this study was retrospective and enrolled a relatively small sample, which makes statistical correlation among clinical presentations, pathological changes and survivin expression difficult. In addition, recurrence appeared in the first 1~4 year after excision in previous studies.<sup>(19-21)</sup> The observation period in this study was too short for enough clinical events to correlate with survivin expression. Second, the study was a qualitative analysis and correlations between the degree of survivin expression and pathologic changes and clinical presentations could not be made. More cases should be included in future studies.

### Conclusions

The results of this study demonstrate that survivin has a novel pathological pattern in cardiac myxomas. These findings have potential significance for understanding the tumor-suppressive activity and apoptotic process in cardiac myxoma in further study. Investigation of embolism and recurrence in myxoma and other types of therapeutic and diagnostic management should be done in the future.

### Acknowledgements

Dr Chu was supported by grants from the National Health Research Institute, Taiwan (NHRI-EX95-9108SC, and NHRI-EX96-9627SI), the National Science Council, Taiwan (NSC 96-2314-B-182-026 and 97-2314-B-182-028-MY2), and CMRPG32057 from Chang Gung Memorial Hospital. Dr. Jung was supported by CMRPG33044 from Chang Gung Memorial Hospital, Taiwan.

## REFERENCES

1. Tamm I, Wang Y, Sausville E, Scudiero DA, Vigna N, Oltersdorf T, Reed JC. IAP-family protein survivin inhibits caspase activity and apoptosis induced by Fas (CD95), Bax, caspases, and anticancer drugs. *Cancer Res* 1998;58:5315-20.
2. Ambrosini G, Adida C, Altieri DC. A novel anti-apoptosis gene, survivin, expressed in cancer and lymphoma. *Nat Med* 1997;3:917-21.
3. Li F, Ambrosini G, Chu EY, Plescia J, Tognin S, Marchisio PC, Altieri DC. Control of apoptosis and mitotic spindle checkpoint by survivin. *Nature* 1998;396:580-4.
4. Chu JS, Shew JY, Huang CS. Immunohistochemical analysis of survivin expression in primary breast cancers. *J Formos Med Assoc* 2004;103:925-31.
5. Kawasaki H, Altieri DC, Lu CD, Toyoda M, Tenjo T, Tanigawa N. Inhibition of apoptosis by survivin predicts shorter survival rates in colorectal cancer. *Cancer Res* 1998;58:5071-4.
6. Sarela AI, Macadam RC, Farmery SM, Markham AF, Guillou PJ. Expression of the antiapoptosis gene, survivin, predicts death from recurrent colorectal carcinoma. *Gut* 2000;46:645-50.
7. Sarela AI, Scott N, Ramsdale J, Markham AF, Guillou PJ. Immunohistochemical detection of the anti-apoptosis protein, survivin, predicts survival after curative resection of stage II colorectal carcinomas. *Ann Surg Oncol* 2001;8:305-10.
8. Lu CD, Altieri DC, Tanigawa N. Expression of a novel antiapoptosis gene, survivin, correlated with tumor cell apoptosis and p53 accumulation in gastric carcinomas. *Cancer Res* 1998;58:1808-12.
9. Koike H, Sekine Y, Kamiya M, Nakazato H, Suzuki K. Gene expression of survivin and its spliced isoforms associated with proliferation and aggressive phenotypes of prostate cancer. *Urology* 2008;72:1229-33.
10. Grossman D, McNiff JM, Li F, Altieri DC. Expression and targeting of the apoptosis inhibitor, survivin, in human melanoma. *J Invest Dermatol* 1999;113:1076-81.
11. Adida C, Haioun C, Gaulard P, Lepage E, Morel P, Briere J, Dombret H, Reyes F, Diebold J, Gisselbrecht C, Salles G, Altieri DC, Molina TJ. Prognostic significance of survivin expression in diffuse large B-cell lymphomas. *Blood* 2000;96:1921-5.
12. Li F, Ling X. Survivin study: an update of "what is the next wave"? *J Cell Physiol* 2006;208:476-86.
13. Andersen MH, Svane IM, Becker JC, Straten PT. The universal character of the tumor-associated antigen survivin. *Clin Cancer Res* 2007;13:5991-4.
14. Kang PM, Yue P, Izumo S. New insights into the role of apoptosis in cardiovascular disease. *Circ J* 2002;66:1-9.
15. Chu PH, Jung SM, Wu HH, Chien LY, Hsueh C, Chu JJ, Lee YS. Apoptosis in primary cardiac tumours. *Int J Clin Pract* 2004;58:564-7.
16. Suzuki M, Hamada M, Hiwada K. Apoptosis in cardiac myxoma. *Ann Intern Med* 2000;132:681.
17. Hofstra L, Dumont EA, Thimister PW, Heidendal GA, DeBruine AP, Elenbaas TW, Boersma HH, van Heerde WL, Reutelingsperger CP. In vivo detection of apoptosis in an intracardiac tumor. *JAMA* 2001;285:1841-2.
18. Burke AP, Virmani R. Cardiac myxoma. A clinicopathologic study. *Am J Clin Pathol* 1993;100:671-80.

19. Reynen K. Cardiac myxomas. *N Engl J Med* 1995;333:1610-7.
20. Pucci A, Gagliardotto P, Zanini C, Pansini S, di Summa M, Mollo F. Histopathologic and clinical characterization of cardiac myxoma: review of 53 cases from a single institution. *Am Heart J* 2000;140:134-8.
21. Pinede L, Duhaut P, Loire R. Clinical presentation of left atrial cardiac myxoma. A series of 112 consecutive cases. *Medicine (Baltimore)* 2001;80:159-72.
22. Acebo E, Val-Bernal JF, Gomez-Roman JJ, Revuelta JM. Clinicopathologic study and DNA analysis of 37 cardiac myxomas: a 28-year experience. *Chest* 2003;123:1379-5.
23. Terracciano LM, Mhawech P, Suess K, D'Armiento M, Lehmann FS, Jundt G, Moch H, Sauter G, Mihatsch MJ. Calretinin as a marker for cardiac myxoma. Diagnostic and histogenetic considerations. *Am J Clin Pathol* 2000;114:754-9.
24. Deshpande A, Venugopal P, Kumar AS, Chopra P. Phenotypic characterization of cellular components of cardiac myxoma: a light microscopy and immunohistochemistry study. *Hum Pathol* 1996;27:1056-9.
25. Goldman BI, Frydman C, Harpaz N, Ryan SF, Loiterman D. Glandular cardiac myxomas. Histologic, immunohistochemical, and ultrastructural evidence of epithelial differentiation. *Cancer* 1987;59:1767-75.
26. Chu PH, Jung SM, Yeh CH, Yeh TS, Wang CL. Mucin gene expression in cardiac myxoma. *Int J Clin Pract* 2004;58:306-9.
27. Chu PH, Jung SM, Yeh TS, Lin HC, Chu JJ. MUC1, MUC2 and MUC5AC expressions in cardiac myxoma. *Virchows Arch* 2005;446:52-5.

## 生存素於心臟黏液瘤的表現

林祐賸<sup>1</sup> 容世明<sup>1</sup> 吳雪華<sup>2</sup> 許慈芳<sup>2</sup> 蔡鋒鈞<sup>3</sup> 朱肇基<sup>3</sup> 林萍章<sup>3</sup> 褚柏顯<sup>2</sup>

**背景：**心臟的黏液瘤是心臟原發性腫瘤中最常見的一種，它常常在病人臨床及免疫組織上有多樣的表現。生存素，它是一個抗細胞凋零的蛋白質，對於形成黏液瘤有可能扮演一個重要的角色。因此，這個研究主在研究生存素在心臟黏液瘤中表現的形態。

**方法：**這個研究包含了 40 個因心臟黏液瘤，經過切除的病人及其切除的組織。病人的臨床表徵，及腫瘤的免疫組織化學染色皆詳實記錄，且分析彼此相關聯性。

**結果：**在這族群中，包含 24 (60%) 女性和 16 (40%) 男性，而其平均年齡為 42 歲。所有腫瘤的發生皆為偶發性而非家族性。病人的臨床表徵為：無症狀佔 20%，喘佔 40%，中風佔 15%，胸口痛佔 12%，發燒佔 12%；腫瘤位置皆在左心房。黏液瘤的位置或造成的臨床表現和病理積分，如血管增生，發炎現象，細胞數比率，玻璃質，鈣化或栓塞，都無明顯不同，或與生存素有相互統計相關聯。生存素的在黏液瘤細胞的細胞質中均存在，且表現於大多數檢體中。

**結論：**生存素在黏液瘤細胞的細胞質中有很強的表現。因而，藉由這個發現可以合理的推測在黏液瘤的細胞凋零過程中可能扮演一個重要的角色。

(長庚醫誌 2011;34:360-6)

**關鍵詞：**生存素，心臟黏液瘤，細胞凋零

長庚醫療財團法人嘉義長庚紀念醫院 心臟內科；長庚醫療財團法人林口長庚紀念醫院 解剖病理科，<sup>2</sup>心臟內科，<sup>3</sup>心臟外科；長庚大學 醫學院

受文日期：民國99年7月8日；接受刊載：民國100年1月5日

通訊作者：褚柏顯醫師，長庚醫療財團法人林口長庚紀念醫院 心臟內科。桃園縣333龜山鄉復興街5號。

Tel.: (03)3281200轉8162; Fax: (03)3271192; E-mail: pchu@cgmh.org.tw