

Facial Asymmetry: Etiology, Evaluation, and Management

You-Wei Cheong, MD; Lun-Jou Lo, MD

Facial asymmetry is common in humans. Significant facial asymmetry causes both functional as well as esthetic problems. When patients complain of facial asymmetry, the underlying cause should be investigated. The etiology includes congenital disorders, acquired diseases, and traumatic and developmental deformities. The causes of many cases of developmental facial asymmetry are indistinct. Assessment of facial asymmetry consists of a patient history, physical examination, and medical imaging. Medical imaging is helpful for objective diagnosis and measurement of the asymmetry, as well as for treatment planning. Components of soft tissue, dental and skeletal differences contributing to facial asymmetry are evaluated. Frequently dental malocclusion, canting of the occlusal level and midline shift are found. Management of facial asymmetry first aims at correcting the underlying disorder. Orthognathic surgery is performed for the treatment of facial asymmetry combined with dental occlusal problems. A symmetrical facial midline, harmonious facial profile and dental occlusion are obtained from treatment. Additional surgical procedures may be required to increase or reduce the volume of skeletal and soft tissue components on both sides to achieve better symmetry. (*Chang Gung Med J 2011;34:341-51*)



Dr. Lun-Jou Lo

Key words: facial asymmetry, evaluation, surgical treatment

Perfectly bilateral face and body symmetry is largely a theoretical concept that seldom exists in living organisms. Right-left differences occur everywhere in nature where two bilateral congruent parts present in an entity. Humans frequently experience functional as well as morphological asymmetries, e.g. right and left handedness as well as preference for one eye or one leg in performing a particular task. Some of these asymmetries are embryonically or genetically determined and encoded in the central nervous system.⁽¹⁾ Preferential laterality for some anomalies is striking, such as cleft lip, which occurs

more commonly on the left side. Left-right tooth crown size asymmetry, evident by measurement but not by visual inspection, is also a normal state in the general population.⁽²⁾ Slight facial asymmetry can be found in normal individuals, even in those with aesthetically attractive faces. This minor facial asymmetry is common, usually indiscernible and does not require any treatment. The point at which 'normal' asymmetry becomes 'abnormal' cannot be easily defined and is often determined by the clinician's sense of balance and the patient's sense of imbalance.⁽¹⁾ By collating photographs of the right and left

From the Department of Plastic and Reconstructive Surgery and Chang Gung Craniofacial Research Center, Chang Gung Memorial Hospital at Linkou, Chang Gung University College of Medicine, Taoyuan, Taiwan.

Received: Feb. 15, 2011; Accepted: Apr. 25, 2011

Correspondence to: Dr. Lun-Jou Lo, Department of Plastic and Reconstructive Surgery, Chang Gung Memorial Hospital at Linkou, 5, Fusing St., Gueishan Township, Taoyuan County 333, Taiwan (R.O.C.) Tel.: 886-3-3281200 ext. 2855; Fax: 886-3-3285818; E-mail: lunjoulo@cgmh.org.tw

sides of a 'normal' face with their respective mirror images, three faces can be visualized; the original face, the two left sides, and the two right sides. Often these three faces from the same individual are distinctly different.⁽³⁾ An example using 3-dimensional photography is demonstrated in Fig. 1.

It has been reported that in cases of minor facial asymmetry, the right hemiface is usually wider than the left hemiface with the chin deviated to the left.⁽⁴⁾ Facial asymmetry affects the lower face more frequently than the upper face. Severt and Proffit reported frequencies of facial laterality of 5%, 36% and 74% in the upper, middle and lower thirds of the face.⁽⁵⁾ The lower part of the face deviates more frequently and at greater distances than the upper and middle parts. One explanation is that the period of growth of the mandible is longer. Chew et al reported asymmetry in 35.8% of 212 patients with dentofacial deformities, with the majority of cases in patients with class III occlusal deformity.^(6,7) He suggested that special attention be paid to class III patients to detect any asymmetry. Class III is more common in Asians than in Caucasians, so is a reasonable assumption that there are more patients with facial

asymmetry among the normal population in Asia than in Western countries.

Etiology of facial asymmetry

Facial asymmetry may be associated with class I occlusion, but is more frequently associated with class II and III occlusions. In some instances the asymmetry is secondary to condylar hyperplasia or hypoplasia, ankylosis of the temporomandibular joint, displaced condylar fractures, or hemifacial microsomia. The etiology of facial asymmetry for many other cases is, however, still unknown. Facial asymmetry can be summarized and divided into three main categories, (1) congenital, originating prenatally; (2) developmental, arising during growth with inconspicuous etiology; and (3) acquired, resulting from injury or disease, as shown in the Table 1.⁽⁸⁻¹⁰⁾ Kawamoto et al divided the causes of an idiopathic laterally deviated mandible into 2 categories.⁽¹¹⁾ The first group involves alteration of the cranial base and glenoid fossa which leads to displacement of the mandible. This includes muscular torticollis, unilateral coronal craniosynostosis and deformational plagiocephaly.⁽¹²⁻¹⁵⁾ The second category




Fig. 1 (A) This 3-dimensional photograph of a normal adult man taken by a 3 dMD system shows a grossly symmetrical face. The face image was adjusted in the standard frontal view. The facial midline was defined, and a mirror image technique was performed. (B) This is a manipulated image in which the right side of the face was replaced by a mirror image of the left side. Likewise (C) this is an image of the two right sides of the face. (B) and (C) represent perfectly symmetric faces. The original image and the two manipulated images look different. Comparisons between (B) and (C) show apparent differences, notably in the cheek fullness, mouth angles, and chin.

Table 1. Etiology of Facial Asymmetry

Congenital	Developmental	Acquired
Cleft lip and palate	Cause unknown	Temporomandibular joint ankylosis
Tessier craniofacial cleft		Facial trauma
Hemifacial microsomia		Childhood radiotherapy
Neurofibromatosis		Fibrous dysplasia
Torticollis		Other facial tumors
Craniosynostosis		Unilateral condylar hyperplasia
Vascular disorders		Romberg's disease
Others		Others

ry involves condylar anomalies which result in hypoplastic or hyperplastic growth of the condyle. Examples include condylar fracture, condylar hyperplasia, and condylar arthritis and hemifacial microsomia.^(16,17)

The developmental type of facial asymmetry is idiopathic and non-syndromic in nature, and is not uncommonly seen in the general population. The asymmetry is not observed at birth or in infancy, and appears gradually, usually becoming apparent in the teenage years. There is no obvious history of facial trauma or detectable disease causing the asymmetry. One possible source is habitual chewing on one side, which is responsible for increased skeletal development on the ipsilateral side.⁽¹⁸⁾ Persistent sleep on one side may be another cause. Haraguchi et al suggested that the etiology of facial asymmetry can be divided between those with genetic origins and those with environmental origins.⁽¹⁹⁾ Neurofibromatosis is one cause of facial asymmetry caused by genetic factors. It is also noted that in cleft lip and palate, the pathology more often occurs on the left side and this phenomenon probably has a genetic basis.⁽²⁰⁾ Intrauterine pressure on the fetus head, as well as pressure in the birth canal during parturition can cause molding of the skull bones and facial bones, causing observable craniofacial asymmetry. However this problem is usually transient and the skull and facial bones return to their normal shape within a few weeks to few months. Non-hereditary conditions that cause facial asymmetry include osteochondroma of the mandibular condyle, which may affect the form and function

of the temporomandibular joint, which in turn causes mandibular deviation and facial asymmetry.⁽²¹⁻²⁴⁾ Trauma, arthritis and infection within the temporomandibular joint can lead to ankylosis of the joint.⁽²⁵⁾ In a growing child, this condition can lead to unilateral mandibular underdevelopment on the affected side.⁽²⁶⁾ Cohen used the term 'hemi-asymmetries' in discussion of craniofacial asymmetry. He further classified these conditions into hemi-hyperplasia, hemi-hypoplasia, hemi-atrophy and other miscellaneous entities.⁽²⁷⁾

Clinical implications

Based on the craniofacial structures involved, facial asymmetry can be classified into dental, skeletal, soft tissue and functional components. Common causes of dental asymmetry are early loss of deciduous teeth, a congenital missing tooth or teeth, and habits such as thumb sucking. Skeletal asymmetry may involve one bone such as the maxilla or mandible, or it may affect a number of skeletal structures on one side of the face, as in hemifacial microsomia. When one side of osseous development is affected, the contralateral side will most inevitably be influenced resulting in compensational or distorted growth. Muscular asymmetry can occur in conditions such as hemifacial microsomia and cerebral palsy. Abnormal muscle function, as in masseter hypertrophy, can itself cause an asymmetrical appearance of the face, as well as contribute to dental and skeletal asymmetry because of abnormal muscle pull. Fibrosis of the sternocleidomastoid muscle as seen in torticollis may create evident craniofacial deformation if left untreated for a period of time.⁽¹⁵⁾ Not only facial but also endocranial morphology is affected and distorted. The deformation becomes more severe with time. Functional asymmetry may result from the mandible being deflected laterally if occlusal interferences prevent proper intercuspation in the centric position. These functional deviations may be caused by a constricted maxillary arch or a local factor such as a malpositioned tooth. In some cases, temporomandibular joint derangement, such as an anteriorly displaced disc, may result in a midline shift during mouth opening caused by interference in mandibular translation on the affected side. However, a combination of these factors is often present. Proper evaluation is needed to arrive at the correct diagnosis. Reyneke et al recommended a classi-

fication system based on the positions of three anatomical areas, namely the maxilla, mandibular body and mandibular symphysis, in relation to the facial midline, as well as the presence of occlusal canting. The authors provided a simple method to identify an appropriate orthodontic and surgical approach for each specific type of asymmetry.⁽¹⁰⁾

Clinically detectable facial asymmetry may be associated with more occult abnormalities elsewhere in the facial skeleton. For example clinically evident chin deviation may be associated with significant horizontal and vertical asymmetry in paired skeletal landmarks in the upper, middle and lower face. This might complicate planning by distorting the reference plane.⁽²⁸⁾ Facial asymmetry may cause a number of problems in patients, including undesirable cosmesis, malocclusion, altered movement of the temporomandibular joint and other temporomandibular joint problems such as pain and clicking.

Evaluation of facial asymmetry

Patients with facial asymmetry are evaluated through clinical assessment, photography, cephalography, and sometimes 3-dimensional computed tomography. Clinical examination reveals asymmetry in the sagittal, coronal and vertical dimensions. It remains the most important diagnostic tool in the evaluation of facial asymmetry. Clinical assessment starts with ascertaining the patient's chief complaint and evaluating the medical history. Clinical examination involves visual inspection of the entire face, palpation to differentiate soft tissue and bony defects, comparison of the dental midline with the facial midline, inspection of symmetry between the bilateral gonial angle and mandibular body lower border, determination of the amount of gingival show per side, and evaluation of malocclusion, occlusal canting, inclination of the anterior teeth, open bites, maximal interincisal opening, mandibular deviation, and the temporomandibular joint. However body posture, mannerisms and hairstyle may hide asymmetry and mislead the treatment plan.⁽²⁹⁾ Most patients notice horizontal or transverse discrepancy more often than vertical and sagittal asymmetry.

The dental midline should be evaluated in the following positions: opening mouth, in centric relation, at initial contact, and in centric occlusion. True dental and skeletal asymmetry will show similar midline discrepancies in centric relation and in cen-

tric occlusion. Asymmetry due to occlusal interference may result in a mandibular functional shift on initial tooth contact. The shift can be either in the same direction or opposite direction of the dental or skeletal discrepancy and may actually accentuate or mask the asymmetry. In addition, functional asymmetry related to temporomandibular joint derangement should be excluded. The presence of a canted occlusal plane could be the result of a unilateral increase in the vertical length of the mandibular ramus and condyle. The maxilla and temporal bone supporting the glenoid fossa could be at different levels on each side of the head. Clinically the canted occlusal plane is readily detected by asking the patient to bite on a tongue blade to determine how it relates to the inter-pupillary plane. At times, patients tilt their heads with a canted orbital level to compensate the lower facial asymmetry, and orbital canting improves after correction of the facial asymmetry.

Vertical skeletal asymmetry associated with a progressively developing unilateral open bite may be the result of condylar hyperplasia or neoplasia. Asymmetry in the bucco-lingual relationship, e.g. a unilateral posterior cross bite, should be carefully assessed to determine whether the cause is skeletal, dental or functional. Dental arch asymmetries could occur because of local factors such as early loss of a deciduous tooth or they could be associated with the rotation of the entire dental arch and its supporting skeletal base. Assessment of the overall shape of the maxillary and mandibular arches from an occlusal view may disclose not only side to side asymmetries but also differences in the bucco-lingual angulation of the teeth. It is important to realize that expansion of the dental arch in the presence of skeletal constriction may adversely affect the stability of the correction. Arch asymmetry could also be due to rotation of the entire maxilla or mandible. In addition to bilateral structural comparison, deviation of midline structures such as the dorsum and tip of the nose, the philtrum and the chin point needs to be determined.

In many cases, clinical examination needs to be supplemented by other diagnostic modalities such as dental casts, face bow transfer and various imaging techniques to accurately localize the asymmetric structures. In radiographic assessment, a number of projections are available to identify the location and cause of facial asymmetry. The lateral view on cephalometry provides limited useful information on

asymmetry in the ramal height, mandibular length and gonial angle. It is limited by the fact that the right and left structures are superimposed on each other and there are different distances from the film and x-ray source resulting in significant differences in magnification. On the other hand, the panoramic view can be a useful projection. The skeletal and dental structures of the maxilla and mandible are subjectively assessed with relative ease. The presence of gross anomalies, and supernumerary or missing teeth can be detected. The shape and height of the mandibular ramus and condyles on both sides can be compared. The cephalometric postero-anterior projection is a valuable tool in the study of the right and left structures since they are located at equal distance from the film and x-ray source (Fig. 2). The postero-anterior view can be obtained at the centric occlusion and open mouth positions to determine the extent of functional deviation. It is recommended that a horizontal line be drawn through the bilateral zygomatico-frontal sutures to act as the horizontal axis in the construction of the horizontal and midsagittal reference planes. A vertical line perpendicular to this horizontal axis is drawn to pass through

the crista galli. This vertical line approximates the anatomic midsagittal plane of the head. The nasion and the anterior nasal spine are noted to fall very near this plane 90% of the time.⁽³⁰⁾ Perpendicular lines from the bilateral structures can now be drawn and the distance from the midsagittal reference line can be measured and compared to determine discrepancies in height as well as the distances between the bilateral structures and the midline. In addition, the maxillary and mandibular dental midlines are compared to the skeletal midline. Stereophotogrammetry using two or more cameras, configured as a stereopair to generate a 3-dimensional image of the face by triangulation, has been reported. This provides a useful three-dimensional assessment of facial soft tissue asymmetry before and after orthognathic surgery.⁽³¹⁾ More recent devices for 3-dimensional photography have been used (Fig. 3). The image can be used for comparison and quantitative measurement. The precision and accuracy of the 3-dimensional photographs have been validated.⁽³²⁻³⁴⁾ The soft tissue images captured from 3-dimensional photogrammetry are comparable to those obtained from traditional cephalogrammetry.⁽³⁵⁾ Other radiographic modalities

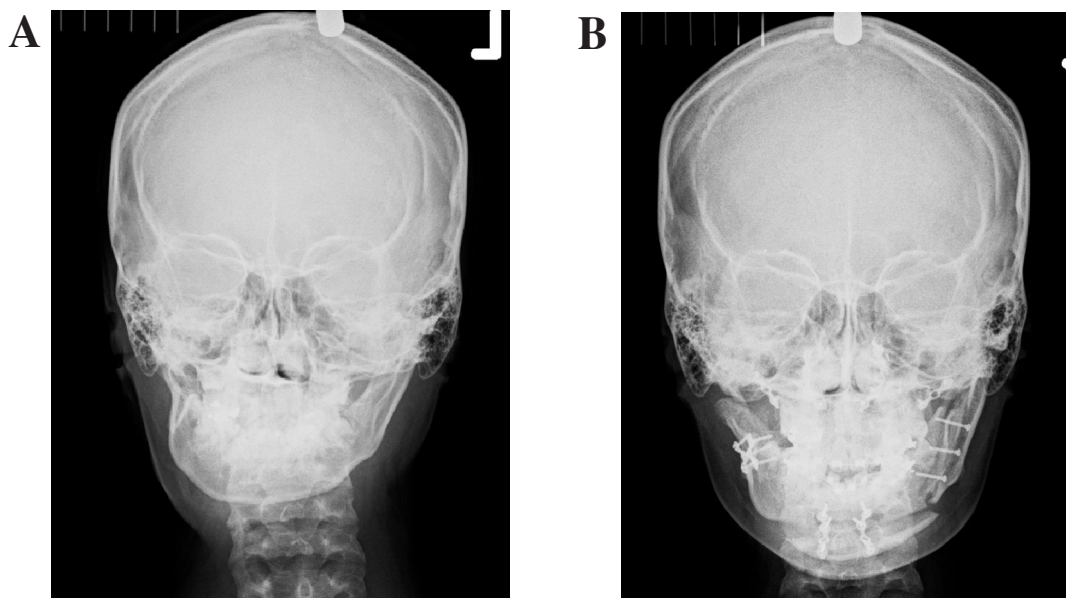


Fig. 2 A posteroanterior view on cephalography of a patient with right temporomandibular joint ankylosis after release and resection of the right condyle shows marked deviation of the mandible to the right side and soft tissue asymmetry (A). The patient received a LeFort I osteotomy for leveling, a left sagittal split of the mandibular ramus for rotation, a release of the right temporomandibular joint and lengthening of the right ramus using a costochondral graft, and a genioplasty for lengthening and advancement, showing improvement of the skeletal as well as soft tissue contour and symmetry (B).




Fig. 3 The 3-dimensional photograph shown in Figure 1A was used to overlap the mirror image of the left side of face on the right side of the face (A). A color map illustrates the differences in depth, showing asymmetry or deformity of the facial contour on both sides. Quantitative differences are shown on the right upper inset scale map. A mirror image of the right side of the face overlapping the left side of the face and the differences are shown in (B).

in the assessment of facial asymmetry include tomography and computed tomography (CT). CT scans both in 2-dimensional and 3-dimensional views can provide excellent details necessary for proper diagnosis and treatment. In addition, three dimensional CT images can also provide information for the fabrication of three-dimensional acrylic skeletal models to facilitate evaluation and surgical planning.⁽³⁶⁾ Cone beam CT scanning has become popular in many dental and maxillofacial centers.

Planning and management

Decisions about intervention for dentofacial deformities depend on patient awareness of the aesthetic problem, the extent of the occlusal deformity, and concomitant sagittal or vertical jaw imbalance.⁽²⁸⁾ Facial asymmetry may involve dental, skeletal and soft tissue components and a combination of orthodontic treatment and orthognathic surgery may be indicated. Treatment of facial asymmetry in preadolescent children is often difficult with unpredictable results. Growth modification with functional appliances has been problematic and the use of a bite-block rarely prevents the need for other treatment modalities.⁽²⁹⁾ A growing patient with mild asymmetry and a functional condyle should receive early orthodontic treatment and be allowed to finish growth before surgery is undertaken.

True dental asymmetry can be managed by

orthodontic treatment alone. Asymmetric extraction sequences and asymmetric mechanics can be employed to correct dental arch asymmetry. Prosthodontic restoration may be indicated in pronounced tooth irregularities. Mild functional deviation can be managed by minor occlusal adjustments. More severe deviations may need orthodontic treatment to align the teeth to obtain proper function. In addition to routine presurgical anteroposterior orthodontic decompensation, intentional transverse orthodontic decompensation may also be required in patients with asymmetry.⁽³⁷⁾ Unilateral vertical maxillary excess and mandibular asymmetry are usually associated with an occlusal cant. This explains why most asymmetries cannot be treated with single-jaw surgery.

More severe asymmetries require a combination of orthodontic and orthognathic management. Clinical practice has shown that surgical correction of the maxillomandibular bony complex may not differ appreciably for etiologically different asymmetries with similar clinical presentations, except that more emphasis is placed on the frontal view during the planning.⁽¹⁰⁾ Correct surgical treatment begins with a proper diagnosis with accurate evaluation of all facial dimensions. Failure to recognize asymmetry until after surgery is viewed by most patients as poor treatment. However the surgical correction of facial asymmetry is challenging because the asym-

metry may involve hard and/or soft tissue in any combination of dimensions. It may involve the maxilla, mandible, symphysis, other parts of the dentofacial skeleton or any combination of these. It is the effective treatment of the hard tissues that brings about the most dramatic change, as soft tissue generally follows underlying bones. Otherwise isolated soft tissue deformities are usually corrected during or after skeletal correction.⁽³⁸⁾ Another problem in the correct planning of treatment is the aspect of growth and development. As a consequence, the planning and extent of surgical correction should be tailored, and secondary surgery could be needed. Unilateral condylar hyperplasia with excessive growth may persist until the age of 23 years. Romberg disease may progress further after 18 years of age. Trauma and tumor causing asymmetry could be late-onset. Minor trauma to the temporomandibular joint in childhood could be unnoticed clinically, but gradually become evident.

Bimaxillary surgery involving a Le Fort I osteotomy and bilateral sagittal split osteotomy is usually required in the surgical management of facial asymmetry. A "single-splint" surgical technique is preferred by a number of surgeons.^(39,40) The maxillomandibular complex is mobilized, the final occlusal splint put on and intermaxillary fixation applied. The position of the maxillomandibular complex is adjusted intraoperatively to achieve the best aesthetic result. The predetermined ideal position may need to be adjusted to compensate for soft tissue deformities, especially in patients with hemifacial microsomia. Intraoperative use of a face bow facilitates the positioning of the maxillomandibular complex in the midline.⁽⁴¹⁾

Surgical planning of two-jaw orthognathic surgery requires 3-dimensional consideration in the sagittal, coronal and horizontal planes. Ideally, the dental midline and skeletal midline are aligned to the facial midline. The intercommissural plane should be parallel to the inter exocanthal plane.⁽⁴⁰⁾ Altug-Atac et al stated that there is no 1:1 relationship between the changes in ramus height and improvement in parallelism of lip commissures to the orbital plane.⁽⁴²⁾ The reason why it is difficult to predict the lip position after orthognathic surgery seems to be that soft-tissue changes in the upper and lower lips after orthognathic surgery occur because of movement of the underlying hard tissue, continuity of the orbicularis oris

muscle, and soft-tissue tension. The degree of soft tissue movement as a response to skeletal structure mobilization may be difficult to predict accurately.^(6,43,44)

Orthognathic surgery can be combined with bone contouring such as a mandibular angle reduction, mandibular inferior border ostectomy, genioplasty, and bony augmentation as well as soft tissue contouring such as buccal fat pad and masseter muscle reduction in the same operation. Minor touch-up procedures, e.g. fat graft injection or subcutaneous liposuction, can be performed as secondary procedures, depending on the requirements (Fig. 4). Choi et al reported on bimaxillary orthognathic surgery combined with a face lift procedure plus the use of a resorbable fixation device.⁽⁴⁵⁾ Ferguson described the definitive surgical correction of hemimandibular hyperplasia with complete mobilization of the inferior alveolar nerve bundle.⁽⁴⁶⁾ Anghinoni et al described the use of a midline mandibular osteotomy to modify the transverse mandibular arch in the management of mandibular asymmetry.⁽⁴⁷⁾

Multiplanar distraction osteogenesis has been applied in the craniofacial region and this technique is used to correct mandibular hypoplasia. Precise and predictable results with distraction osteogenesis require accurate placement of an osteotomy or corticotomy, distraction device placement, vector planning, and selection of a distractor as well as consideration of the effects of the masticatory muscles and surrounding soft tissues that may deviate the tooth bearing segment toward an unexpected position. McCarthy et al reported that only a single osteotomy and two pin sites are required in the execution of multiplanar distraction osteogenesis.⁽⁴⁸⁾ It has been proved that distraction for lengthening the mandibular ramus also increases the soft tissue by increasing the volume of the medial pterygoid muscle, and this may somewhat improve the facial symmetry in patients with hemifacial microsomia.⁽⁴⁹⁾ Ko et al documented increased length of the mandibular ramus after one year with improvement of chin and oral commissure positions.⁽⁵⁰⁾

Summary

When patients complain of facial asymmetry and seek treatment, it is important to search for underlying causes. This entails a thorough history, physical examination, and imaging studies. An

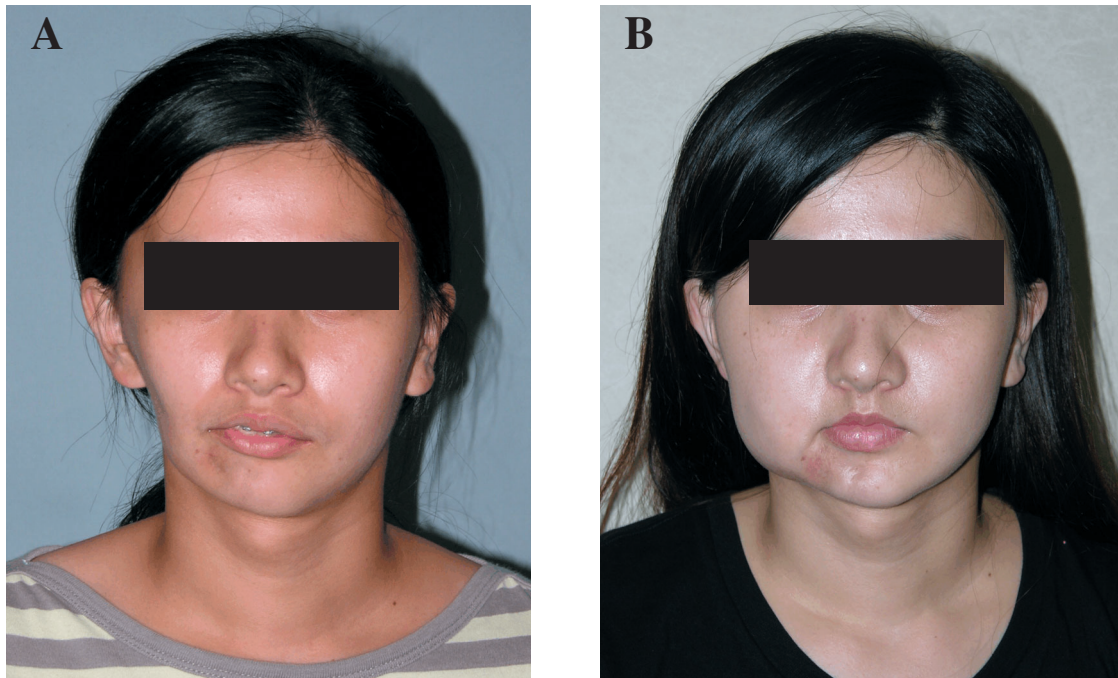


Fig. 4 A 23-year old woman with Romberg's disease on the right side of the face shows marked deficiency of bone and soft tissue on the right side (A). The maxillary and mandibular midline has been shifted to the right side, with a canted dental occlusal plane. She received a maxillary and mandibular osteotomy for restoration of the facial midline and occlusal plane, followed by reconstruction with fat injection to the right side of face, and finally a touch up operation for refinement of facial symmetry (B).

orthodontic consultation is required if there are dental and occlusal problems. Skeletal, dental and soft tissue components contributing to facial asymmetry should be carefully evaluated. The patient's perception of facial asymmetry and expectations about treatment results should be assessed. Inappropriate perceptions and expectations may become a contraindication for treatment. Surgical treatment planning may include staged procedures. The first stage comprises orthognathic surgery, facial bone contouring surgery, genioplasty, and contouring of soft tissues such as the masseter muscle and buccal fat pads. If a second stage operation is required for adjustment of the symmetry, alloplastic implants and fat injection for volume augmentation, as well as bone lessening and liposuction for volume reduction, can be done.

Acknowledgements

The 3-dimensional image study was supported by a grant, CMRPG381601, from Chang Gung Memorial Hospital.

REFERENCES

1. Bishara SE, Burkey PS, Kharouf JG. Dental and facial asymmetries: a review. *Angle Orthod* 1994;64:89-98.
2. Burke PH. Stereophotogrammetric measurement of normal facial asymmetry in children. *Hum Biol* 1971;4:536.
3. Cohen MM Jr. Perspectives of craniofacial asymmetry. Part I. The biology of asymmetry. *Int J Oral Maxillofac Surg* 1995;24:2-7.
4. Haraguchi S, Iguchi Y, Takada K. Asymmetry of the face in orthodontic patients. *Angle Orthod* 2008;78:421-6.
5. Severt TR, Proffit WR. The prevalence of facial asymmetry in the dentofacial deformities population at the University of North Carolina. *Int J Adult Orthodon Orthognath Surg* 1997;12:171-6.
6. Chew MT. Soft and hard tissue changes after bimaxillary surgery in Chinese class III patients. *Angle Orthod* 2005;75:959-63.
7. Chew MT. Spectrum and management of dentofacial deformities in a multiethnic Asian population. *Angle Orthod* 2006;76:806-9.
8. Hegtvedt AK. Diagnosis and management of facial asymmetry. In: Peterson LJ, Indressano AT, Marciani RD, Roser SM, eds. *Oral and Maxillofacial Surgery*. Vol 3.

- Philadelphia: Lippincott, 1993:1400-14.
9. Cohen MM Jr. Perspectives of craniofacial asymmetry. Part III. Common and/or well known causes of asymmetry. *Int J Oral Maxillofac Surg* 1995;24:127-33.
 10. Reyneke JP, Tsakiris P, Kienle F. A simple classification for surgical planning of maxillomandibular asymmetry. *Br J Oral Maxillofac Surg* 1997;35:349-51.
 11. Kawamoto HK, Kim SS, Jarrahy R, Bradley JP. Differential diagnosis of the idiopathic laterally deviated mandible. *Plast Reconstr Surg* 2009;124:1600-9.
 12. Lo LJ, Marsh JL, Pilgram TK, Vannier MW. Plagiocephaly: differential diagnosis based on endocranial morphology. *Plast Reconstr Surg* 1996;97:282-91.
 13. Lo LJ, Marsh JL, Kane AA, Vannier MW. Orbital dysmorphology in unicoronal synostosis. *Cleft Palate Craniofac J* 1996;33:190-7.
 14. Kane AA, Lo LJ, Vannier MW, Marsh JL. Mandibular dysmorphology in unicoronal synostosis and plagiocephaly without synostosis. *Cleft Palate Craniofac J* 1996;33:418-23.
 15. Yu CC, Wong FH, Lo LJ, Chen YR. Craniofacial deformity in patients with uncorrected congenital muscular torticollis: an assessment from 3-dimensional CT imaging. *Plast Reconstr Surg* 2004;113:24-33.
 16. Chen YR, Bendor-Samuel RL, Huang CS. Hemimandibular hyperplasia. *Plast Reconstr Surg* 1996;97:730-7.
 17. Kane AA, Lo LJ, Christensen GE, Vannier MW, Marsh JL. Relationship between bone and muscles of mastication in hemifacial microsomia. *Plast Reconstr Surg* 1997;99:990-7.
 18. Shah SM, Joshi MR. An assessment of asymmetry in the normal craniofacial complex. *Angle Orthod* 1978;48:141-8.
 19. Haraguchi S, Takada K, Yasuda Y. Facial asymmetry in subjects with class III deformity. *Angle Orthod* 2002;72:28-35.
 20. Noordhoff MS, Chen PKT. Unilateral cheiloplasty. In: SJ Mathes, ed. *Plastic Surgery*. 2nd ed. Philadelphia: Saunders Elsevier, 2006;4:165-215.
 21. Wolford LM, Mehra P, Franco P. Use of conservative condylectomy for treatment of osteochondroma of the mandibular condyle. *J Oral Maxillofac Surg* 2002;60:262-8.
 22. Holmlund AB, Gynther GW, Reinholt FP. Surgical treatment of osteochondroma of the mandibular condyle in the adult. A 5-year follow-up. *Int J Oral Maxillofac Surg* 2004;33:549-53.
 23. Ortakoglu K, Akcam T, Sencimen M, Karakoc O, Ozyigit HA, Bengi O. Osteochondroma of the mandible causing severe facial asymmetry: a case report. *Oral Surg Oral Med Oral Pathol Oral Radiol Endod* 2007;103:e21-8.
 24. González-Otero S, Navarro-Cuéllar C, Escrig-de Teigeiro M, Fernández-Alba-Luengo J, Navarro-Vila C. Osteochondroma of the mandibular condyle: resection and reconstruction using vertical sliding osteotomy of the mandibular ramus. *Med Oral Patol Oral Cir Bucal* 2009;14:e194-7.
 25. Carlson ER. Pathologic facial asymmetries. *Atlas Oral Maxillofac Surg Clin North Am* 1996;4:19-35.
 26. Zhi K, Ren W, Zhou H, Gao L, Zhao L, Hou C, Zhang Y. Management of temporomandibular joint ankylosis: 11 years' clinical experience. *Oral Surg Oral Med Oral Pathol Oral Radiol Endod* 2009;108:687-92.
 27. Cohen MM Jr. Perspectives of craniofacial asymmetry. Part IV. Hemi-asymmetries. *Int J Oral Maxillofac Surg* 1995;24:134-41.
 28. Ko EWC, Huang CS, Chen YR. Characteristics and corrective outcome of face asymmetry by orthognathic surgery. *J Oral Maxillofac Surg* 2009;67:2201-9.
 29. Waite PD, Urban SD. Management of facial asymmetry. In: Miloro M, Ghali GE, Larsen PE, Waite P, eds. *Peterson's Principles of Oral and Maxillofacial Surgery*. Hamilton, Ontario, Canada: BC Decker Inc, 2004:1205-19.
 30. Harvold E. Cleft lip and palate. Morphologic studies of facial skeleton. *Am J Orthod* 1954;40:493-506.
 31. Hajeer MJ, Ayoub AF, Millet DT. Three-dimensional assessment of facial soft tissue asymmetry before and after orthognathic surgery. *Br J Oral Maxillofac Surg* 2004;42:396-404.
 32. Aldridge K, Boyadjiev SA, Capone GT, DeLeon VB, Richtsmeier JT. Precision and error of three-dimensional phenotypic measures acquired from 3 dMD photogrammetric images. *Am J Med Genet A* 2005;138A:247-53.
 33. Weinberg SM, Naidoo S, Govier DP, Martin RA, Kane AA, Marazita ML. Anthropometric precision and accuracy of digital three-dimensional photogrammetry: comparing the Genex and 3 dMD imaging systems with one another and with direct anthropometry. *J Craniofac Surg* 2006;17:477-83.
 34. Lübbers HT, Medinger L, Kruse A, Grätz KW, Matthews F. Precision and accuracy of the 3 dMD photogrammetric system in craniomaxillofacial application. *J Craniofac Surg* 2010;21:763-7.
 35. Incrapera AK, Kau CH, English JD, McGrory K, Sarver DM. Soft tissue images from cephalograms compared with those from a 3D surface acquisition system. *Angle Orthod* 2010;80:58-64.
 36. Sailer HF, Haers PE, Zollikofer CP, Warnke T, Caris FR, Stucki P. The value of stereolithographic models for pre-operative diagnosis of craniofacial deformities and planning of surgical corrections. *Int J Oral Maxillofac Surg* 1998;27:327-33.
 37. Proffit WR, Turvey TA. Dentofacial asymmetry. In: Proffit WR, White RP Jr, eds. *Surgical Orthodontic Treatment*. St Louis: Mosby, 1991:483-549.
 38. Facial asymmetry. In: Whitaker LA, Salyer KE, Munro IR, Jackson IT, eds. *Atlas of Craniofacial Surgery*. St Louis: CV Mosby, 1982:258-317.

39. Bergeron L, Yu CC, Chen YR. Single-splint technique for correction of severe facial asymmetry: correlation between intraoperative maxillomandibular complex roll and restoration of mouth symmetry. *Plast Reconstr Surg* 2008;122:1535-41.
40. Yu CC, Bergeron L, Lin CH. Single-splint technique in orthognathic surgery: intraoperative checkpoints to control facial symmetry. *Plast Reconstr Surg* 2009;124:879-86.
41. Chen YR, Lo LJ, Kyutoku S, Noordhoff MS. Facial midline and symmetry: modified face bow. *Plast Reconstr Surg* 1992;90:126-8.
42. Altug-Atac AT, Grayson BH, McCarthy JG. Comparison of skeletal and soft-tissue changes following unilateral mandibular distraction osteogenesis. *Plast Reconstr Surg* 2008;121:1751-9.
43. Koh CH, Chew MT. Predictability of soft tissue profile changes following bimaxillary surgery in skeletal class III Chinese patients. *J Oral Maxillofac Surg* 2004;62:1505-9.
44. Jung YJ, Kim MJ, Baek SH. Hard and soft tissue changes after correction of mandibular prognathism and facial asymmetry by mandibular setback surgery: three-dimensional analysis using computerized tomography. *Oral Surg Oral Med Oral Pathol Oral Radiol Endod* 2009;107:763-71.
45. Choi JY, Choi JP, Lee YK. Simultaneous correction of hard- and soft-tissue facial asymmetry: Combination of orthognathic surgery and face lift using a resorbable fixation device. *J Craniofac Surg* 2010;21:363-70.
46. Ferguson JW. Definitive surgical correction of the deformity resulting from hemimandibular hyperplasia. *J Cranio Maxillofac Surg* 2005;33:150-7.
47. Anghinoni ML, Magri AS, Di Blasio A, Toma L, Sesenna E. Midline Mandibular osteotomy in an asymmetric patient. *Angle Orthod* 2009;77:1008-14.
48. McCarthy JG, Williams JK, Grayson BH, Crombie JS. Controlled multiplanar distraction of the mandible: device development and clinical application. *J Craniofac Surg* 1998;9:322-9.
49. Mackool RJ, Hopper RA, Grayson BH, Holliday R, McCarthy JG. Volumetric change of the medial pterygoid following distraction osteogenesis of the mandible: an example of the associated soft-tissue changes. *Plast Reconstr Surg* 2003;111:1804-7.
50. Ko EW, Hung KF, Huang CS, Chen PK. Correction of facial asymmetry with multiplanar mandible distraction: a one-year follow-up study. *Cleft Palate Craniofac J* 2004;41:5-12.

顏面不對稱：原因、檢查、和治療

張有為 羅綸洲

顏面不對稱在人類普遍存在，嚴重的不對稱會引起功能上和外觀上的問題，有此問題的病人需要探討其可能致病原因，病因包括先天異常、後天疾病、創傷性、或發育性的問題，很多發育性的顏面不對稱其原因不清楚。檢查包括疾病史、理學檢查、和醫學影像，醫學影像有助於客觀評估診斷，據以做成治療計畫。檢查應該查明是否軟組織、牙齒咬合、以及骨骼成分所造成的差異，牙齒咬合異常、咬合面歪曲、和中線偏離是常見的發現。顏面不對稱的治療首先應該針對致病因做處理，正顎手術可以治療因為合併牙齒咬合異常的顏面不對稱，藉以獲得顏面中線準確、和諧外觀和牙齒咬合。有時候一些額外的手術是必要的，這包括針對軟組織和骨骼的增量或減量的手術，以得到最佳的對稱性。(長庚醫誌 2011;34:341-51)

關鍵詞：顏面不對稱，檢查，外科治療

長庚醫療財團法人林口長庚紀念醫院 整形外科，顏面研究中心；長庚大學 醫學院

受文日期：民國100年2月15日；接受刊載：民國100年4月25日

通訊作者：羅綸洲醫師，長庚醫療財團法人林口長庚紀念醫院 整形外科。桃園縣333龜山鄉復興街5號。

Tel.: (03)32812005轉2855; Fax: (03)3285818; E-mail: lunjoulo@cgmh.org.tw