

Rotator Cuff Lesions with Shoulder Stiffness: Updated Pathomechanisms and Management

Jih-Yang Ko, MD; Feng-Sheng Wang¹, PhD

Few previous studies have investigated the pathomechanism and managements of rotator cuff lesions with shoulder stiffness. Based on observations by Codman in 1934, frozen shoulder presumably relates to rotator cuff tendinitis. In the past six decades, tended to discriminate primary frozen shoulder from secondary shoulder stiffness due to shoulder disorders such as rotator cuff lesions or trauma. Intrinsic degeneration and outlet acromial spur impingement are reported as pathogenic causes of rotator cuff lesion. Although patients with rotator cuff lesions with shoulder stiffness or adhesive capsulitis (frozen shoulder) may have similar complaints about pain and motion limitation, the pathological reactions in these disorders remain unclear. In our investigation of clinical vignettes of shoulder stiffness, inflammation-mediated adhesions in the subacromial bursa in rotator cuff lesions, and changes in inflammatory cytokine levels have been linked to myofibroblast recruitment in the subacromial bursa. Our study provides the first indication that increased interleukin -1 β expression and myofibroblast recruitment in the subacromial bursa are correlated with rotator cuff lesions with shoulder stiffness. Increased inflammatory cytokine concentrations in the lesions also provide new molecular insight into the pathological role of the subacromial bursa in the development of shoulder stiffness in rotator cuff lesions. Although rotator cuff repair is a shoulder-tightening procedure and is not recommended until resolution of the shoulder stiffness in rotator cuff lesions with stiff shoulder, our clinical evidence-based survey suggests that a combined procedure of manipulation, lysis of adhesions, acromioplasty, and rotator cuff repair is a useful procedure if the symptoms do not improve 3 months of aggressive rehabilitation. (*Chang Gung Med J* 2011;34:331-40)



Dr. Jih-Yang Ko

Key words: rotator cuff lesion, shoulder stiffness, pathomechanism

In 1934, Codman reported a disorder of muscle spasm and stiffness of the glenohumeral joint and coined the term “frozen shoulder”.⁽¹⁾ The report mentions that this disorder is “difficult to define, treat and explain from the view of pathology”. The symp-

oms are presumably related to tendinitis of the rotator cuff. Codman’s report is probably the first observation combining rotator cuff lesions with shoulder stiffness. Other groups interpreted frozen shoulder as an idiopathic global limitation of humeroscapular

From the Department of Orthopaedic Surgery; ¹Medical Research, Kaohsiung Chang Gung Memorial Hospital and Chang Gung University College of Medicine, Kaohsiung, Taiwan.

Received: Jan. 4, 2011; Accepted: Apr. 25, 2011

Correspondence to: Dr. Jih-Yang Ko, Department of Orthopaedic Surgery, Kaohsiung Chang Gung Memorial Hospital, 123, Dapi Rd., Niasong, Kaohsiung 833, Taiwan (R.O.C.) Tel.: 886-7-7317123 ext. 8003; Fax: 886-7-7354309; E-mail: kojy@cgmh.org.tw

motion resulting from contracture and loss of compliance of the glenohumeral joint capsule.⁽²⁾ Secondary shoulder stiffness is defined as either a known intrinsic or extrinsic precursor that causes shoulder pain and dysfunction and ultimately leads to global stiffness.

Rotator cuff lesions are one of the most common shoulder joint disorders. Symptoms include pain, limited motion, weakness, and functional disability. Although nonsurgical or surgical treatment leads to satisfactory results in the majority of rotator cuff lesions,⁽³⁻⁵⁾ few studies have discussed the pathogenic mechanisms and management of rotator cuff tears associated with secondary shoulder stiffness.⁽⁶⁾ In this review, we surveyed the pathomechanism of rotator cuff lesions with shoulder stiffness and offered an emerging modality concept for the treatment of these combined disorders.

Clinical course of shoulder stiffness

The available literature implicating the clinical course of rotator cuff lesion with shoulder stiffness is scarce. We interpret the progression of frozen shoulder to imply rotator cuff lesions with shoulder stiffness. Frozen shoulder usually undergoes three phases, freezing, a frozen state, and then thawing. However, secondary shoulder stiffness usually lasts longer if the underlying disease does not improve.

Painful phase: "freezing"

The freezing phase begins when a patient initially notices aching pain, which often begins at night and persists during the day.^(7,8) Lying on or turning onto the affected shoulder often disturbs sleep. This phase reportedly persists between 2 and 9 months.⁽⁹⁾

Progressive stiffness phase: A "frozen" state

The phase of progressive stiffness lasts between 3 and 12 months, and ultimately results in a classic frozen shoulder.^(1,9) Stiffness may progress to an extent that shoulder motion becomes limited in all directions. Pain is usually less than in the initial freezing phase and is often much more focused.

Resolution phase: "thawing"

This stage is characterized by slow gains in motion and comfort, and can be as short as 4 weeks, especially with aggressive operative treatment. However, for patients treated nonoperatively, the

shoulder motion slowly improves over 12 to 42 months. Some authors report a significant number of patients with persistent symptoms lasting for as long as 6 to 10 years.^(10,11) With or without aggressive treatment, the patient's symptoms usually resolve, but often motion restrictions persist.⁽¹²⁾ Patients who have rotator cuff lesions and shoulder stiffness may display a pattern of restricted asymmetric range of forward elevation, internal rotation, and cross-body adduction, which may not be resolved in the presence of rotator cuff lesions.^(2,13)

Etiology of shoulder stiffness

Data on predisposing factors in patients with secondary shoulder stiffness are scarce. From our clinical investigation, we assume primary and secondary shoulder stiffness may have similar etiologic causes.

Age: The bulk of adults who present with a stiff shoulder of either primary or secondary origin are generally between 40 and 60 years old.^(2,8) In our study, the diabetic patients who underwent concomitant treatment for rotator cuff tears and shoulder stiffness were older than the non-diabetic patients.⁽¹⁴⁾

Injuries: Shoulder stiffness is associated with a minor traumatic incident contemporary with the onset of symptoms in most patients. This may also imply that inflammatory reactions coincide with the development of shoulder stiffness.

Diabetes Mellitus: Patients with diabetes mellitus have an increased risk of developing limited joint motion, including shoulder and joint disorders.^(7,15) The incidence of frozen shoulder among diabetics averages approximately 10 to 20% but may be as high as 35%. Pathomechanically, high circulating glucose levels may accelerate aging of certain proteins by forming and accumulating irreversible cross-links between adjacent protein molecules.^(16,17)

Shoulder stiffness reportedly antedates diabetic symptoms.⁽¹⁸⁾ The longer a patient has been receiving insulin, the higher the risk of developing shoulder stiffness, and the greater the resistance to all treatment modalities.⁽¹⁹⁻²¹⁾ Because of the refractory nature of shoulder stiffness in insulin-dependent diabetes, early intervention has been suggested to prevent progressive disability.⁽²⁰⁻²²⁾ Indeed, the only one patient who needed arthroscopic capsular release after concomitant treatment for rotator cuff tears and shoulder stiffness had insulin-dependent diabetes.⁽¹⁴⁾

Cardiac Disease: For many years, clinicians have been keen to associate coronary artery disease with shoulder stiffness. Ernstene and Kinell reviewed 133 consecutive cases of myocardial infarction, and found 17 patients whose original presenting symptom was unrelenting pain in the shoulder region.⁽²³⁾ Therefore, a good cardiac examination is justified to rule out an unrecognized coronary artery disorder.

Pulmonary Disorders: Frozen shoulder reportedly occurs more frequently in patients afflicted with emphysema and chronic bronchitis.⁽²⁴⁾ Whether the severity or the duration of pulmonary disorders correlates with shoulder stiffness requires further verification.

Neurological Conditions: Riley et al. reported a 13% incidence of frozen shoulder in patients with Parkinson's disease but only a 1.7% rate in age-matched controls.⁽²⁵⁾ Other groups mentioned a 25% incidence of frozen shoulder in patients who had subarachnoid hemorrhage.⁽²⁶⁾

Imaging of rotator cuff lesions with shoulder stiffness

Plain radiographs are needed to rule out abnormalities in the bone (e.g., tumors) or in the local soft tissues (e.g., calcific deposits or heterotopic ossification). A hooked-shape acromion, or spurs on the acromion or acromio-clavicular joints may be visible in patients with rotator cuff tears. In shoulder stiffness, a bone scan is useful to rule out a neoplastic disorder or autonomic dystrophy; however, it has not proved useful in the diagnosis, management, or prognosis of a frozen shoulder.⁽⁷⁾ Proponents of arthrography claim it is useful in standardizing the classification and selecting patients for clinical research.^(27,28) However, no correlation between arthrographic findings and treatment outcome has been found.⁽²⁹⁾ Magnetic resonance imaging (MRI), arthrography or sonography, affords the clinical advantage of identifying partial or complete rotator cuff tears in patients who present with shoulder stiffness.

Arthroscopy for Rotator Cuff Lesions with Stiffness: Reported arthroscopic findings immediately after a successful manipulative release included intra-articular hemarthroses, avulsion of the inferior capsule adjacent to the labrum, tears in the rotator interval capsule with occasional labral avulsions, and capsular tears anterosuperiorly or anteroinferiorly.^(7,22,30,31) Arthroscopy has been used in shoulder stiff-

ness to (1) evaluate pathologic changes to the glenohumeral joint and subacromial space, (2) recognize problems associated with shoulder stiffness (e.g., a tendon or labral tear), (3) determine the local effects of closed manipulation, and (4) surgically address pathologic lesions when indicated.

Pathogenesis of rotator cuff lesions

Intrinsic degeneration and outlet acromial spur impingement are reportedly prominent pathological reactions in rotator cuff lesions.^(32,33) However, surgical procedures for this type of shoulder disorder vary with different pathological viewpoints. For example, if the rotator cuff lesions are attributable to extrinsic impingement, adequate acromial decompression becomes an important part of the surgical procedure. If the lesions are mainly related to intrinsic degeneration, factors that aggravate the degenerative process should be avoided and modalities for protecting the cuff from progressive degeneration are recommended when treating the lesions.

Most cases of complete tears of the rotator cuff are mainly complicated by partial tears in the lesions. We prospectively reported the etiology of rotator cuff lesions and demonstrated the pathologic changes in the acromion and rotator cuff and the surgical results of patients with partial tears of the rotator cuff.⁽³⁴⁾ The degenerative grade of the rotator cuff on MRI was based on the criteria of Zlatkin and Iannotti et al.⁽³⁵⁾ The pathology of the anterior acromion was graded from a modified system by Ozaki et al⁽³²⁾ and Panni et al (Fig. 1).⁽³⁶⁾

MRI of the rotator cuff has shown more severe pathologic changes in articular side tears than bursal side tears. On the contrary, bursal side tears have more severe histological changes in the acromion. The clinical vignettes indicate that articular side tears of the rotator cuff mainly associate with intrinsic degenerative changes, whereas bursal side tears are mainly caused by subacromial impingement on the underlying more mildly degenerated rotator cuff. Therefore, management of both extrinsic subacromial impingement and intrinsic degeneration of the rotator cuff is recommended in the treatment of rotator cuff lesions.

Pathomechanism of shoulder stiffness

The early term for "freezing" of a frozen shoulder in the interface of the rotator cuff and subacromi-

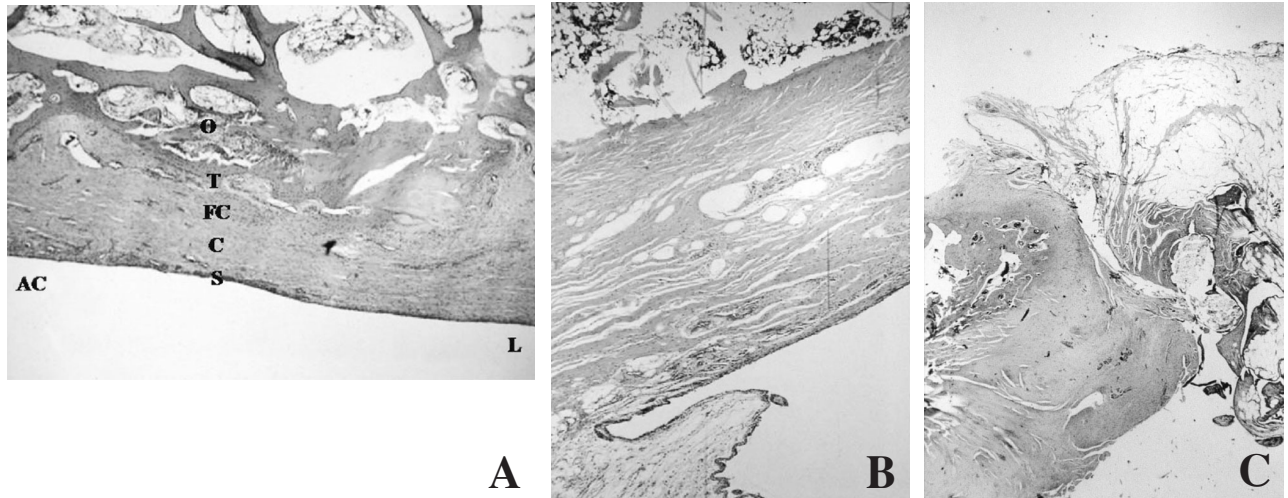


Fig. 1 Light micrographs of the anterior acromion showing different pathologic gradings for rotator cuff lesions. (A) Normal histologic features (grade 0) on the lateral side of the acromion (L) and a grade 1 degenerative pattern on the acromioclavicular joint side of the acromion (AC) are shown. The histologic features of the anterior acromion are well observed. O: osseous; T: tidemark; FC: fibrocartilaginous; C: collagenous; S: synovial layers (hematoxylin and eosin; original magnification 100x). (B) Grade 2 pathology shows a moderate degenerative pattern in the acromion (hematoxylin and eosin; magnification 100x). (C) A light micrograph of the anterior acromion shows a severe grade 3 degenerative pattern (hematoxylin and eosin; original magnification 100x).

al space was “periarthrititis”.⁽¹⁾ However, very few reports supported the involvement of this anatomical interface in the development of frozen shoulder or shoulder stiffness at that time. Most pathomechanical studies have focused on the development of primary frozen shoulder.^(7,37-45) Lundberg found increased collagen deposits in the joint capsule and further proposed inflammation as an important reaction leading to stiffness, pain, and capsular fibrosis.⁽⁴⁶⁾ Some investigators associated the fibrotic changes in the glenohumeral capsule to Dupuytren’s contracture in the palm, and mentioned the presence of an inflammatory component in the synovial and subsynovial layers, but absence of this component in the shoulder capsule.^(37,40,47) Bunker and Anthony reported active fibroblastic proliferation in association with myofibroblasts in the coracohumeral ligament and rotator interval in patients with frozen shoulder.⁽³⁷⁾ Transforming growth factor β , platelet-derived growth factor, and hepatocyte growth factor are detectable in the early inflammatory stages of primary and secondary shoulder stiffness.⁽⁴³⁾

Although patients with adhesive capsulitis (frozen shoulder) or rotator cuff lesions with shoulder stiffness have similar complaints of pain and

motion limitation, the pathologic reactions among these disorders remain unclear. During surgery, the release of a contracted rotator interval and coracohumeral ligament increases external rotation of the shoulder and excision of the adhesive subacromial bursa and lysis of the subacromial adhesions promotes shoulder motion.⁽⁷⁾ Adhesions are more severe in the subacromial space than in the glenohumeral joint (Fig. 2). These intraoperative findings suggest that adhesions in the subacromial bursa are a potent cause of rotator cuff lesions with shoulder stiffness. It is rational to propose that shoulder stiffness is related to inflammation-induced adhesions in the subacromial bursa in these lesions. Moreover, changes in inflammatory cytokine levels are presumably linked to myofibroblast recruitment in the subacromial bursa.

We enrolled patients who underwent surgery for rotator cuff tears with and without shoulder stiffness. The surgical indications included MRI findings of a complete rotator cuff tear and shoulder stiffness for more than 3 months despite supervised physical therapy. The criteria for shoulder stiffness were loss of passive range of motion (ROM) $\geq 50\%$ with normal ROM considered to be 180° forward flexion, 180°

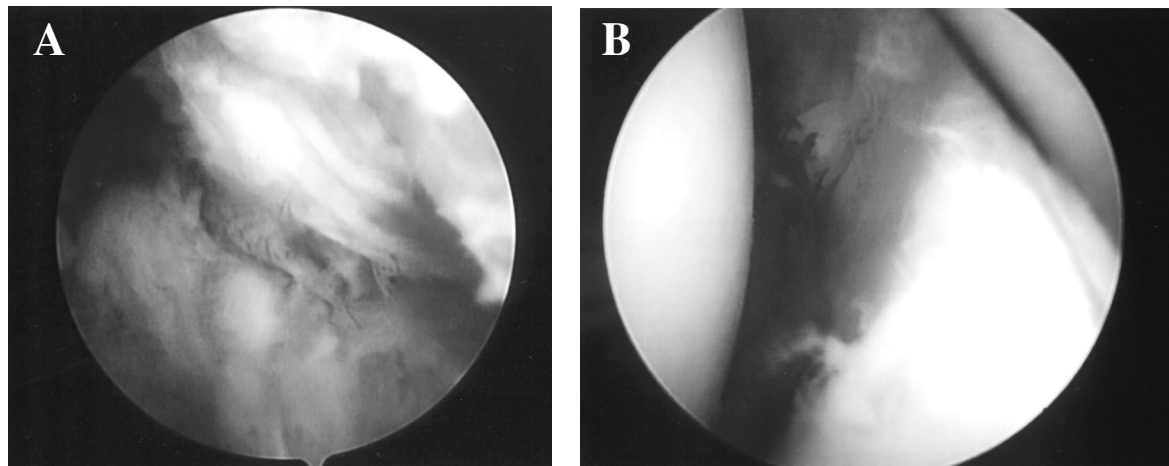


Fig. 2 Differential arthroscopic findings in the subacromial space and glenohumeral joint in a patient with rotator cuff lesion and shoulder stiffness. (A) Severe inflammation and adhesions in the subacromial space are noted during surgery. (B) Less severe inflammatory and adhesive changes are noted in the glenohumeral joint compared with the subacromial space in the same patient. The adhesive changes mainly involve the synovium instead of the humeral head or glenoid cavity.

abduction, 90° external rotation, and 90° internal rotation. Preoperative ROM deficits were added together to determine the sum of the ROM deficit (SROMD). Patients were defined as having shoulder stiffness if the SROMD $\geq 270^\circ$.⁽⁴⁸⁾

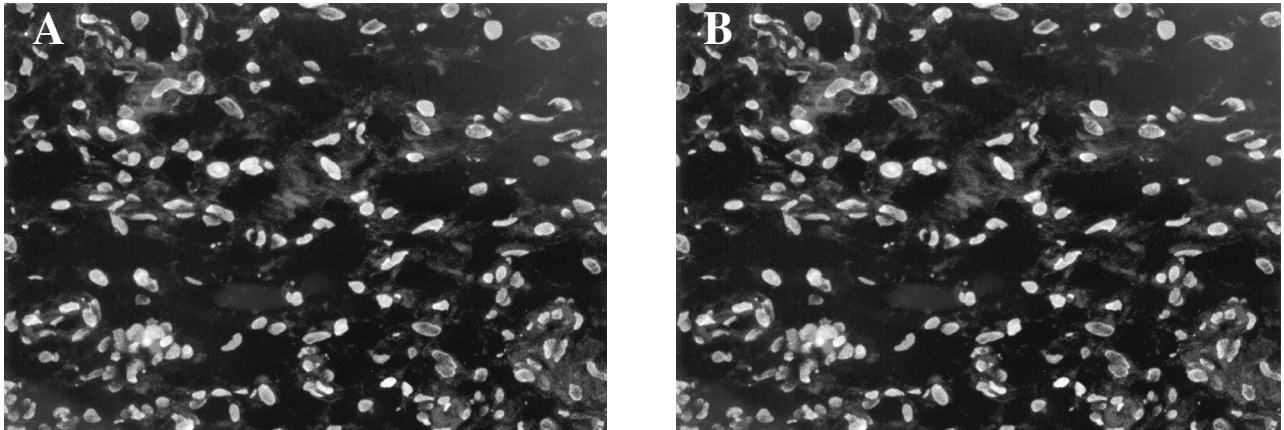
During the operation, shoulder stiffness was confirmed under anesthesia. After acromioplasty, obvious adhesions were noted between the acromion, deltoid, and rotator cuff. We also detected interleukin (IL)-1 β , IL-6, and tumor necrosis factor (TNF)- α levels and myofibroblast apoptosis in the subacromial bursa and subacromial fluid in patients with rotator cuff tears with and without shoulder stiffness. We found that patients with shoulder stiffness had increased IL-1 β expression in the lesion tissue, in association with increased joint fluid IL-1 β , IL-6 and TNF- α concentrations. Increased subacromial bursa and joint fluid IL-1 β expression correlated with a preoperative deficit in shoulder motion and preoperative Constant scores. Patients with shoulder stiffness had increased myofibroblasts, however, those without shoulder stiffness had decreased myofibroblasts but increased apoptotic myofibroblasts in the subacromial synovium of the rotator cuff (Fig. 3). We provided the first cellular and molecular indications that an increased IL-1 β level and myofibroblast recruitment in the subacromial bursa at least partly contribute to rotator cuff lesion with shoulder stiff-

ness. Moreover, we also provided new insight into the pathological role of the subacromial bursa in the development of shoulder stiffness in rotator cuff lesions.⁽⁴⁸⁾

Primary frozen shoulder and secondary shoulder stiffness in rotator cuff lesions may share similar mechanisms

The definition of primary frozen shoulder is a global limitation of the shoulder joint without causative etiology. Although most authors tend to differentiate rotator cuff lesions with shoulder stiffness from primary frozen shoulder, some authors link rotator cuff lesions to painful stiffness of the shoulder.^(1,7,41) Advanced imaging technology and molecular biology have shown that some patients with primary frozen shoulder presumably have trivial changes in the tissues around the shoulder joint.

Our novel findings revealed the pathological role of proinflammatory cytokines and myofibroblasts in rotator cuff lesion with shoulder stiffness. Other groups reported similar findings in the lesion tissue of primary frozen shoulder.^(37,38,43) We concede that these different types of shoulder disorders may share similar pathological mechanisms. Our in-depth analytic results alternatively disclosed the mysteries of primary frozen shoulder.



Figs. 3 Representative immunofluorescence photographs of α -SM and TUNEL staining of the subacromial bursa from patients with and without shoulder stiffness. Cells with α -SM staining display red fluorescence in the periphery and cytoplasm. Apoptotic cells express positive TUNEL staining with green fluorescence in the nucleus. (A) In patients with shoulder stiffness, intensive fibroblastic cells with α -SM expression are seen in the subacromial tissue. A few α -SM stained cells coexpress TUNEL. (B) In patients without stiffness, few cells express α -SM immunostaining. Those cells codisplay evident TUNEL expression. Specimens were counterstained by DAPI with blue fluorescence (Original magnification 200 \times).

Treatment

There are few reports on the management of rotator cuff tears with shoulder stiffness. Some authors suggest that in patients with rotator cuff tears with secondary shoulder stiffness, the shoulder stiffness should be treated initially because a rotator cuff repair is a “shoulder-tightening” procedure and might increase stiffness postoperatively.^(6,7)

The choice of treatment for shoulder stiffness should be tailored according to the duration and severity of symptoms. There are six treatment modalities⁽⁷⁾ including (1) supportive treatment, such as immobilization, heat, ice, ultrasound, massage, and others, (2) medications given orally, topically, or parenterally (local and intra-articular), such as nonsteroid anti-inflammatory agents, analgesics, narcotics, corticosteroids, and hyaluronates, (3) stretching exercises or traction, (4) injections of fluid, arthrographic dye, or medication for joint distention to release capsular contracture, (5) manipulative therapy with or without anesthesia to release adhesions or contracted structures, and (6) surgical release of adhesions by open or arthroscopic surgery.

Surgical release should be considered only after failed nonoperative treatment. Contraindications for surgical release include significant depression, autonomic dystrophy. In addition, arthroscopic capsular release is absolutely contraindicated in patients who

cannot tolerate the surgical stress of a fluid challenge (e.g. renal or cardiac failure). The major advantage of an open surgical release is the opportunity to safely handle and visualize adhesions outside the joint. When rotating the upper extremity and palpating between tissue planes, it becomes easier to identify tight bands that restrict motion. The main advantages of arthroscopic release include (1) an accurate release of the contracted capsular structures, (2) increased mobility of musculotendinous units without compromising their integrity, and (3) ability to identify other intrinsic pathology that may have initiated or contributed to the shoulder stiffness.^(7,22,30,31)

Although it was previously suggested that shoulder stiffness be managed before rotator cuff repair, patients usually need to wait a significant length of time for improvement of shoulder motion before rotator cuff tears can be repaired. In addition, shoulder stiffness may not be relieved, especially in the presence of rotator cuff lesions. This is a challenging task for orthopedic doctors with patients who have rotator cuff tears and shoulder stiffness. Tauro reported the surgical results of arthroscopic cuff repair without release for rotator cuff tears and stiffness,⁽⁴⁹⁾ and found that patients with severe shoulder stiffness might not do well with cuff repair alone. Combined cuff repair and capsular release was recommended for these patients. Many reports mention

that moderate preoperative shoulder stiffness does not alter the clinical outcome of rotator cuff repair with arthroscopic release and manipulation.^(50,51) Based on analysis of our results of increased inflammatory cytokine and myofibroblast apoptosis in the subacromial bursa, we recommend that subacromial debridement and lysis of adhesions be performed meticulously in the concomitant treatment of rotator cuff tear and shoulder stiffness.⁽⁴⁸⁾

Forty-eight patients with shoulder stiffness (52 shoulders) underwent treatment for rotator cuff tears and associated shoulder stiffness concomitantly.⁽²²⁾ We performed a combined procedure of manipulation, lysis and debridement of adhesions, anterior acromioplasty, and repair of the rotator cuff. Forty-three patients (47 shoulders) were available for follow-up for a minimum of two years. Ten of these patients (11 shoulders) had diabetes mellitus. Twenty-seven shoulders displayed partial tears of the rotator cuff, 15 shoulders displayed complete tears and 5 shoulders showed massive tears. Postoperative pain control included patient-controlled analgesia, intramuscular opioid injections and non-steroidal anti-inflammatory medication. Pendulous exercise and passive elevation were started on the second postoperative day followed by active-assisted exercises including elevation, external rotation and internal rotation 3 to 4 days postoperatively. Active exercise was started when the patient could tolerate it, usually 7-10 days after surgery. For patients with massive rotator cuff tearing, the shoulder was immobilized in a Velpeau bandage for 3 days. Pendulous exercise and passive elevation were started 3-4 days postoperatively, followed by active-assisted exercises 10 days later. After a postoperative follow-up of 48.6 ± 18.0 months, each patient showed significant improvement in subjective, objective, and strength scoring as well as in the total Constant score. Comparison of the scores among the three types of rotator cuff tears revealed that our modalities significantly improved the total function score. Moreover, patients with partial tears of the rotator cuff had significantly better scores than did those with complete tears or large tears.

Based on the clinical investigation, we suggest that aggressive non-surgical treatment is feasible first for patients with rotator cuff lesions and shoulder stiffness. A combined procedure of manipulation, lysis of adhesions, acromioplasty and repair of the

rotator cuff is optionally recommended if symptoms do not improve after 3 months of aggressive rehabilitation.

Conclusions

Because of limitations in diagnostic technologies, orthopedists in the past six decades have tended to discriminate primary frozen shoulder from secondary shoulder stiffness due to disorders such as rotator cuff lesions or trauma. With the advanced imaging technologies and molecular biology in the 21st century, orthopedists have found that some cases of primary frozen shoulder may result from trivial lesions in the rotator cuff. The pathomechanism between primary frozen shoulder and secondary shoulder stiffness in rotator cuff lesions seems to be similar and involves the increased expression of proinflammatory cytokines and myofibroblast recruitment.

Rotator cuff repair is reportedly a shoulder-tightening procedure, a conventional surgery that was not recommended until resolution of the shoulder stiffness in rotator cuff lesions with stiff shoulder. Our clinical vignettes reveal that a combined procedure of manipulation, lysis of adhesions, acromioplasty, and rotator cuff repair is a useful procedure if symptoms do not improve after 3 months of aggressive rehabilitation.

Acknowledgements

This work was supported in part by grants CMRP 1132 from Chang Gung Memorial Hospital and NMRPG1102 from the National Science Council, Taiwan.

REFERENCES

1. Codman EA. The Shoulder. Boston: Todd, 1934:216-24.
2. Matsen FA III, Lippitt SB, Sidles JA, Harryman DT II. Practical Evaluation and Management of the Shoulder. Philadelphia: WB Saunders, 1994:19-109.
3. Cofield RH. Current concepts review. Rotator cuff disease of the shoulder. *J Bone Joint Surg Am* 1985;67:974-9.
4. Budoff JE, Nirschl RP, Guidi EJ. Debridement of partial – thickness tears of the rotator cuff without acromioplasty: Long-term follow-up and review of the literature. *J Bone Joint Surg Am* 1998;190:733-48.
5. Cartsman GM. Arthroscopic acromioplasty for lesions of the rotator cuff. *J Bone Joint Surg Am* 1990;72:169-80.
6. Warner JP, Greis PE. The treatment of stiffness of the

- shoulder after repair of the rotator cuff. *J Bone Joint Surg Am* 1997;79:1260-9.
7. Harryman DT II, Lazarus MD, Rozencaiw R. The stiff shoulder. In: Rockwood CA Jr, Masten FA III, eds. *The Shoulder*. 2nd ed. Philadelphia, PA: WB Saunders Co., 1998:1064-112.
 8. Murnaghan JP. Adhesive capsulitis of the shoulder: current concepts and treatment. *Orthopaedics* 1988;11:153-8.
 9. Reeves B. The natural history of the frozen shoulder syndrome. *Scand J Rheumatol* 1975;4:193-6.
 10. Clarke GR, Willis LA, Fish WW, Nichols PJ. Preliminary studies in measuring range of motion in normal and painful stiff shoulders. *Rheumatol Rehabil* 1975;14:39-46.
 11. Shaffer B, Tibone JE, Kerlan RK. Frozen shoulder: A long term follow-up. *J Bone Joint Surg Am* 1992;74:738-46.
 12. Binder AI, Bulgen DY, Hazleman BL, Roberts S. Frozen shoulder: A long-term prospective study. *Ann Rheum Dis* 1984;43:361-4.
 13. Hsu SY, Chan KM. Arthroscopic distension in the management of frozen shoulder. *Int Orthop* 1991;15:79-83.
 14. Hsu SL, Ko JY, Chen SH, Wu RW, Chou WY, Wang CJ. Surgical results in rotator cuff tears with shoulder stiffness. *J Formos Med Assoc* 2007;106:452-61.
 15. Rosenbloom AL. Limitation of finger joint mobility in diabetes mellitus. *J Diabet Complications* 1989;3:77-87.
 16. Hogan M, Cerami A, Bucala R. Advanced glycosylation endproducts block the antiproliferative effect of nitric oxide. Role in the vascular and renal complications of diabetes mellitus. *J Clin Invest* 1992;90:1110-5.
 17. Makita A, Radoff S, Rayfield EJ, Yang Z, Skolnik E, Delaney V, Friedman EA, Cerami A, Vlassara H. Advanced glycosylation end products in patients with diabetic nephropathy. *N Engl J Med* 1991;325:836-42.
 18. Seibold JR. Digital sclerosis in children with insulin-dependent diabetes mellitus. *Arthritis Rheum* 1982;25:1357-61.
 19. Morén-Hybbinette I, Moritz U, Sherstén B. The clinical picture of the painful diabetic shoulder – natural history, social consequences and analysis of concomitant hand syndrome. *Acta Med Scand* 1987;221:73-82.
 20. Fisher L, Kurtz A, Shipley M. Association between cheiroarthropathy and frozen shoulder in patients with insulin dependent diabetes mellitus. *Br J Rheumatol* 1986;25:141-6.
 21. Sattar MA, Luqman WA. Periarthritis: Another duration-related complication of diabetes mellitus. *Diabetes Care* 1985;8:507-10.
 22. Ogilvie-Harris DJ, Biggs DJ, Fitsialos DP, MacKay M. The resistant frozen shoulder. Manipulation versus arthroscopic release. *Clin Orthop Relat Res* 1995;319:238-48.
 23. Ernstene AC, Kinell J. Pain in the shoulder as a sequel to myocardial infarction. *Arch Intern Med* 1940;66:800-6.
 24. Saha NC. Painful shoulder in patients with chronic bronchitis and emphysema. *Am Rev Respir Dis* 1966;94:455-6.
 25. Riley D, Lang AE, Blair RD, Birnbaum A, Beid B. Frozen shoulder and other shoulder disturbances in Parkinson's disease. *J Neurol Neurosurg Psychiatry* 1989;52:63-6.
 26. Bruckener FE, Nye CJ. A prospective study of adhesive capsulitis of the shoulder ("frozen shoulder") in a high risk population. *Q J Med* 1981;50:191-204.
 27. Neviasser JS. Adhesive capsulitis of the shoulder. *J Bone Joint Surg* 1945;27:211-22.
 28. Neviasser TJ. Adhesive capsulitis. *Orthop Clin North Am* 1987;18:439-43.
 29. Binder AI, Bulgen DY, Hazleman BL, Tudor J, Wraight P. Frozen shoulder: An arthrographic and radionuclear scan assessment. *Ann Rheum Dis* 1984;43:365-9.
 30. Harryman DT II, Sidles JA, Matsen FA II. Arthroscopic management of refractory shoulder stiffness. *Arthroscopy* 1997;13:133-47.
 31. Neviasser RJ, Neviasser TJ. Arthroscopy of the shoulder. *Orthop Clin North Am* 1987;18:361-72.
 32. Ozaki J, Fujimoto S, Nakagawa Y, Masuhara K, Tamai S. Tears of the rotator cuff of the shoulder associated with pathological changes in the acromion. *J Bone Joint Surg Am* 1988;70:1224-30.
 33. Neer CA II. Anterior acromioplasty for the chronic impingement syndrome in the shoulder: A preliminary report. *J Bone Joint Surg Am* 1972;54:41-50.
 34. Ko JY, Huang CC, Chen WJ, Chen CE, Chen SH, Wang CJ. Pathogenesis of partial tear of the rotator cuff – a clinical and pathologic study. *J Shoulder Elbow Surg* 2006;15:271-8.
 35. Zlatkin MB, Iannotti JP, Roberts MC, Esterhai JL, Dalinka MK, Kressel HY, Schwartz JS, Lenkinski RE. Rotator cuff tears: diagnostic performance of MR imaging. *Radiology* 1989;172:223-9.
 36. Panni AS, Milano G, Lucania L, Fabbriani C, Logroscino CA. Histological analysis of the coracoacromial arch: correlation between age-related changes and rotator cuff tears. *Arthroscopy* 1996;12:531-40.
 37. Bunker TA, Anthony AA. The pathology of frozen shoulder: A Dupuytren-like disease. *J Bone Joint Surg Br* 1995;177:677-83.
 38. Bunker TA, Reilly J, Baird KS, Hamblen DL. Expression of growth factors, cytokines and matrix metalloproteinases in frozen shoulder. *J Bone Joint Surg Br* 2000;82:768-73.
 39. Galatz LA, Griggs S, Cameron BD, Lannotti JP. Prospective longitudinal analysis of postoperative shoulder function. A ten-year follow-up study of full-thickness rotator cuff tears. *J Bone Joint Surg Am* 2001;83:1052-6.
 40. Hannafin JA, Chiaia TA. Adhesive capsulitis. A treatment approach. *Clin Orthop Relat Res* 2000;372:95-109.
 41. Macnab I. The painful shoulder due to rotator cuff tendinitis. *R I Med J* 1971;54:367-74.
 42. Neviasser JA. Adhesive capsulitis of the shoulder: a study

- of the pathological findings in peri-arthritis of the shoulder. *J Bone Joint Surg* 1945;27:211-22.
43. Rodeo SA, Hannafin JA, Tom J, Warren RF, Wichiewicz TL. Immunolocalization of cytokines and their receptors in adhesive capsulitis of the shoulder. *J Orthop Res* 1997;15:427-36.
 44. Riedel R. Die Versteifung des Schultergelenkes durch Hangenlassen des Armes. *Munch med Wschr* 1916;63:1397.
 45. Simmonds FA. Shoulder pain with particular reference to the frozen shoulder. *J Bone Joint Surg* 1949;31:834-8.
 46. Lundberg BJ. The frozen shoulder: Clinical and radiographical observations. The effect of manipulation under general anesthesia. Structure and glycosaminoglycan content of the joint capsule. Local bone metabolism. *Acta Orthop Scand* 1969;119 suppl: 1-59.
 47. Meulengracht E, Schwartz M. The course and prognosis of peri-arthritis humeroscapularis with special regard to cases with general symptoms. *Acta Med Scand* 1952;143:350-60.
 48. Ko JY, Wang FS, Huang HY, Wang CJ, Tseng SL, Hsu C. Increased IL-1 β expression and myofibroblast recruitment in subacromial bursa is associated with rotator cuff lesions with shoulder stiffness. *J Orthop Res* 2008;26:1090-7.
 49. Tauro JC. Stiffness and rotator cuff tears: incidence, arthroscopic findings, and treatment results. *Arthroscopy* 2006;22:581-6.
 50. Cho NS, Rhee YG. Functional outcome of arthroscopic repair with concomitant manipulation in rotator cuff tears with stiff shoulder. *Am J Sports Med* 2008;36:1323-9.
 51. Oh JH, Kim SH, Lee HK, Jo KH, Bin SW, Gong HS. Moderate preoperative shoulder stiffness does not alter the clinical outcome of rotator cuff repair with arthroscopic release and manipulation. *Arthroscopy* 2008;24:983-91.

旋轉肌袖疾患合併肩僵直——最新病理機轉及治療趨勢

郭繼陽 王逢興¹

文獻上探討旋轉肌袖疾患合併肩僵直的研究很少。Codman 最早提出冷凍肩可能與旋轉肌袖疾患有關，但在這半世紀傾向於把原發性冷凍肩與次發於旋轉肌袖疾患或外傷之肩僵直分開。旋轉肌袖疾患主要是因內在性退化性及外在性肩峰下衝撞現象所引起的，在合併肩僵直之旋轉肌袖疾患病案手術中，我們發現肩峰下滑囊呈現嚴重之發炎及沾粘。我們的研究結果亦指出肩峰下滑囊之發炎性細胞動素 IL-1 β 表現增強及肌纖維母細胞之聚集與旋轉肌袖疾患合併肩僵直有關。旋轉肌袖疾患合併肩僵直之處置有其複雜性，以往之學者建議肩僵直部份須先得到解決才作旋轉肌袖斷裂之縫合，否則縫合之後可能肩關節會更緊。藉由上述之臨床與基礎研究，我們的經驗顯示如果肩僵直積極治療三個月以上無效，同時施行肩峰下滑囊沾黏之解離，肩峰形成術及旋轉肌袖斷裂縫合可達到良好之治療效果。(長庚醫誌 2011;34:331-40)

關鍵詞：旋轉肌袖疾患，肩僵直，病理機轉

長庚醫療財團法人高雄長庚紀念醫院 骨科，¹醫學研究部；長庚大學 醫學院

受文日期：民國100年1月4日；接受刊載：民國100年4月25日

通訊作者：郭繼陽醫師，長庚醫療財團法人高雄長庚紀念醫院 骨科。高雄市833鳥松區大埤路123號。

Tel.: (07)7317123轉8003; Fax: (07)7354309; E-mail: kojy@cgmh.org.tw