

## Clinical Results of All-inside Meniscal Repair Using the FasT-Fix Meniscal Repair System

Chih-Wei Chiang, MD; Chung-Hsun Chang, MD; Chun-Ying Cheng, MD;  
Alvin Chao-Yu Chen, MD; Yi-Sheng Chan, MD; Kuo-Yao Hsu, MD; Wen-Jer Chen, MD

**Background:** The meniscus plays a key role in the functioning of the knee. At the present time, meniscal repair has become the main treatment for meniscal tear. Compared to open surgery, arthroscopic meniscal repair has become popular because of shorter time need for the operation, the smaller wound, and better accessibility to the tear portion, which is particularly difficult during open surgery. Three arthroscopic techniques are widely used, namely inside-out, outside-in, and all-inside. Arthroscopy all inside meniscal repair has the lowest neurovascular injury rate.

**Methods:** This study prospectively evaluated 31 consecutively treated patients to determine the effectiveness/safety of arthroscopic meniscal repair using the FasT-Fix repair system. The inclusion criteria for this study were: vertical full-thickness tear > 10 mm in length; location of the meniscal tear < 6 mm from the meniscocapsular junction; repair of the meniscus solely with the FasT-Fix system; no former meniscus surgery; and no evidence of arthritis during arthroscopy. Anterior cruciate ligament (ACL) deficient knees were reconstructed using a hamstring autograft at the time of the meniscal repair. Follow-up examinations consisted of Lysholm knee score, Tegner activity score and radiographic evaluation.

**Results:** After an average of 3 years follow-up, no symptoms of meniscal tears were found in 30/31 of the cases. For patients with isolated meniscal repair or concurrent ACL reconstruction, the Lysholm and Tegner activity scores had significantly improved postoperatively. No neurovascular or other major complications were directly associated with the use of the device.

**Conclusions:** Arthroscopic all-inside repair using the FasT-Fix device appears to be a safe and effective procedure.

*(Chang Gung Med J 2011;34:298-305)*

**Key words:** meniscal tear, arthroscopy, all-inside meniscal repair

The meniscus plays a key role in the functioning of the knee. As more has begun to be understood about the anatomical structure and unique function

of the meniscus, a preference for preserving more of the meniscus after injury has arisen. Although meniscal repair was first performed more than 100

---

From the Division of Sports Medicine, Department of Orthopaedic Surgery, Chang Gung Memorial Hospital at Linkou, Chang Gung University College of Medicine, Taoyuan, Taiwan.

Received: Apr. 22, 2010; Accepted: Nov. 18, 2010

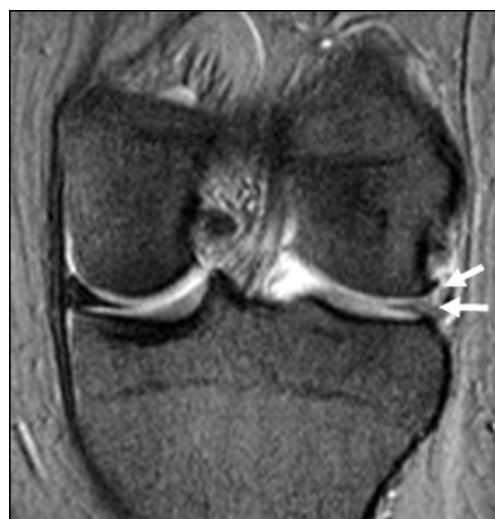Correspondence to: Dr. Yi-Sheng Chan, Department of Orthopaedic Surgery Division of Sports Medicine, Chang Gung Memorial Hospital at Linkou, 5, Fusing St., Gueishan Township, Taoyuan County 333, Taiwan (R.O.C.) Tel.: 886-3-3281200 ext. 3882; Fax: 886-3-3278113; E-mail: chan512@adm.cgmh.org.tw

years ago by Annandale,<sup>(1)</sup> it did not become widely practiced until the last two decades. Hiroshi Ikeuchi was the first orthopedic surgeon to perform meniscal repair using arthroscopic techniques about forty years ago.<sup>(2)</sup> Compared to open surgery, arthroscopic meniscal repair has become popular because of the shorter operation time, the smaller wound, and the improved accessibility to the tear portion, which is particularly difficult during open surgery. In addition, improvements in arthroscopic techniques and instrumentation in recent years have simplified the procedure.

Presently, three arthroscopic techniques are widely used, namely inside-out, outside-in, and all-inside. Furthermore, the use of biodegradable products for the all-inside approach has become very popular because it is less time consuming and reduces the risk of development of grave neurovascular complications.<sup>(3,4)</sup> However, several reports have mentioned complications that are directly associated with these devices such as chondral injuries and synovitis.<sup>(5-8)</sup> Another concern is the inferior strength of these devices compared with vertical sutures, which may be a critical factor that contributes to meniscal healing according to some previous biomechanical studies.<sup>(9-11)</sup> Currently, a plethora of devices for all-inside meniscal repair are being used. Most of these have been tested *in vitro*; however, clinical results are not available for the majority. One of the devices that has recently been introduced is the FasT-Fix meniscal repair system (Smith & Nephew, Andover, MA, U.S.A.). This device combines the advantages of the all-inside technique with strong biomechanical properties,<sup>(12,13)</sup> and is a modification of the previous Smith & Nephew T-fix device. This system can be used for vertical, horizontal, or oblique meniscal tears. The goal of this study was to evaluate the clinical results and complications of arthroscopic meniscal repairs using the FasT-Fix meniscal repair system in a consecutive series of 31 patients at Chang Gung Memorial Hospital. The study hypothesis was that arthroscopic all-inside meniscal repair with the FasT-Fix device would be a safe procedure and would provide excellent clinical results without major complications. This is the first case-series study describing the clinical results and complications of the FasT-Fix meniscal repair system in Taiwan.

## METHODS

From October 2004 through September 2006, 31 arthroscopic meniscal repairs in 31 consecutive patients were performed by the senior author (YS Chan) using the FasT-Fix Meniscal Repair Suture System (Smith & Nephew) and the arthroscopic technique described below. In this prospective study, pre-operative evaluations included assessment of any effusion of the injured knee joint, the joint's range of motion, the stability of knee joint, the joint line tenderness, and an administration of the McMurray test. All patients had a magnetic resonance image study of the injury to the knee (Fig. 1). The inclusion criteria for this study were (1) a vertical full-thickness tear greater than 10 mm in length, (2) the location of the meniscal tear being less than 6 mm from the meniscocapsular junction,<sup>(14)</sup> (3) fixation of the meniscus solely with the FasT-Fix system, (4) no former meniscus surgery, and (5) no evidence of arthritis during arthroscopy. Isolated anterior cruciate ligament (ACL) deficient knees without concomitant collateral ligamentous injuries were reconstructed using a hamstring autograft at the time as the meniscal repair. Institutional Review Board approval (CGMH 98-0563B) was obtained before initiating the study. All patients gave their informed consent to participate.



**Fig. 1** A 25-year-old male with a basketball injury had experienced pain, locking, and effusion in his left knee for 3 weeks. Magnetic resonance imaging demonstrated a peripheral tear of the lateral meniscus (white arrows).

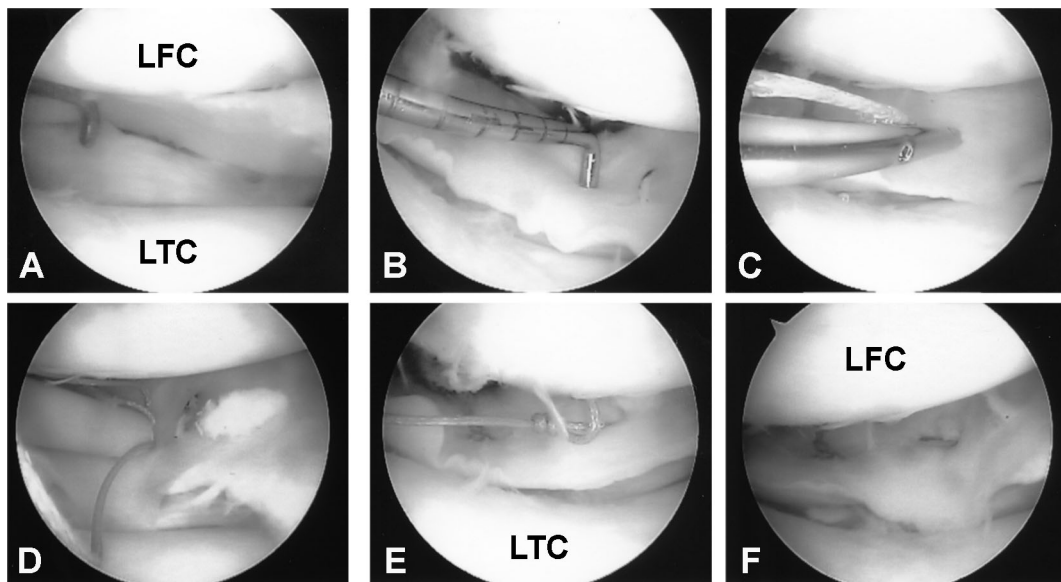
### Surgical technique

General anesthesia was administered to all patients. After diagnostic arthroscopy, the morphology of the meniscus tear was determined (Fig. 2A). The tear length and the rim width were recorded at the time of surgery. In patients with a dislocated bucket-handle tear, reduction was performed. Tear edges were freshened with a meniscus rasp and shaver. Using microfracture awls, multiple perforations were made in the meniscus rim to produce vascular channels and encourage bleeding to stimulate the healing response. Each FasT-Fix device contains two 5-mm polymer suture bar anchors with a pre-tied self-sliding knot of No. 0 nonabsorbable USP (U.S. Pharmacopoeia) braided polyester suture material. In addition, a split cannula facilitates easy insertion of the device into the knee joint, and functions as a depth penetration limiter, and a knot pusher-suture cutter. Using a meniscal depth probe, the desired length of penetration was determined (Fig. 2B) and the depth limiter was trimmed accordingly; this was followed by introduction of the FasT-Fix delivery needle through the split cannula. The needle was then withdrawn from the meniscus using a smooth motion (Fig. 2C). The gold trigger was then slid for-

ward to advance the second implant. For a horizontal suture, the delivery needle was transferred 5 mm sideways, while for a vertical suture, it was placed perpendicular to the tear in order to ensure maximum tension. After the second implant had been inserted, the delivery needle was removed from the knee joint, such that the ends of the sutures were left free (Figs. 2D and E). The pre-tied self-sliding knot was tensioned with the aid of the knot pusher-suture cutter. The sutures were cut with either the knot pusher-suture cutter or with arthroscopic scissors under arthroscopic imaging (Fig. 2F). If the patient had experienced an ACL injury, arthroscopic reconstruction was conducted after the meniscus repair using tendon grafts harvested from the patient's hamstring tendon.

### Postoperative rehabilitation

After the operation, the 18 patients with isolated meniscal repair started non-weight-bearing motion immediately and full weight bearing was permitted at 6 weeks postoperatively. For the 13 patients who had meniscal repair with an ACL reconstruction, they used a hinged brace. In the latter cases, non-weight-bearing motion was restricted to 0–60° for



**Fig. 2** Intraoperative arthroscopic views. (A) Preoperative arthroscopic view. A large lateral meniscus peripheral tear is evident, which is compatible with the magnetic resonance imaging findings. (B) Using a meniscal depth probe, the desired length of penetration is determined. (C) Placement of the first suture bar anchor in the lateral meniscus. (D) The second implant is in place 5 mm from the first implant. (E) After insertion of the second implant, the delivery needle is removed from the knee joint, leaving the free end of the sutures. (F) Final arthroscopic image after cutting the sutures with the knot pusher-suture cutter.

the first two weeks and the range of motion was increased to 0–90° for the next two weeks. Full weight bearing and a full range of motion was permitted at week 6. Jogging was permitted after week 10. Unrestricted activity was permitted at 6 months for patients with isolated meniscal repair and at 9 months for patients with meniscal repair and an ACL reconstruction.

### Follow-up evaluation

Each patient received follow-up, which included both clinical and radiographic evaluations, at regular intervals. All patients had been evaluated preoperatively and this was repeated postoperatively at one month, three months, six months and one year, and annually thereafter. All patients were examined by an independent observer (Chiang CW) who was not involved in the surgery. According to Barrett's criteria,<sup>(15)</sup> a repaired meniscus was considered healed if no joint-line tenderness or effusion was observed, and if the McMurray test was negative at the most recent follow-up. If one or more of these criteria was not met, the technique was classified as a failure. The follow-up examination employed the following scoring systems: Lysholm,<sup>(16)</sup> for document subjective symptoms and Tegner activity score.<sup>(17)</sup> The pre-injury Tegner activity level score and activity level were calculated according to the International Knee Documentation Committee (IKDC) guidelines from patient reports of their activity levels before the knee injury.

### Statistics

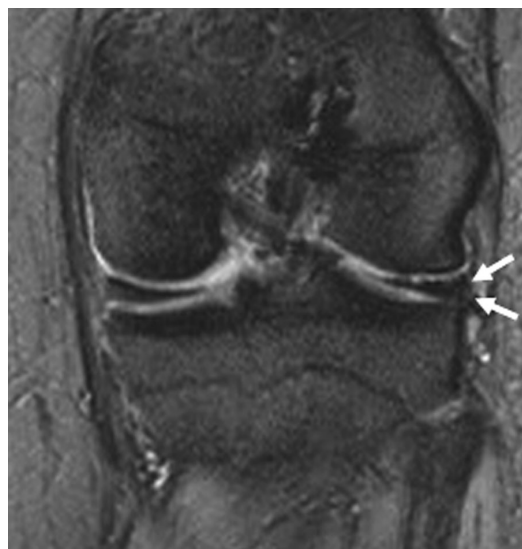Statistical analysis was conducted by an independent statistician who was not associated with the surgical team. A paired *t* test was used for comparison of the preoperative and postoperative Lysholm and Tegner scores. A value of *p* < 0.05 was considered statistically significant. Statistical analysis was performed using the computer program SigmaStat version 2.0 (Aspire Software, Ashburn, VA, U.S.A.).

## RESULTS

The prospective series consisted of 31 patients (19 men and 12 women). No patient loss occurred during follow-up in this series. The average age at the time of meniscal repair was 30.7 years (range, 18–44 years). The average follow-up period was 36

months (range, 24–50 months). Eleven (48%) meniscal tears were rated acute (injury-to-repair interval ≤ 3 weeks), and 12 (52%) tears were rated chronic (injury-to-repair interval > 3 weeks). The mean and range of “injury-to-repair” intervals for the acute and chronic cases were 1.8 weeks (1–3 weeks) and 8.2 weeks (4–12 weeks), respectively. There were 18 (58%) isolated meniscal tears, and 13 (42%) tears were combined with arthroscopic ACL reconstruction. Eighteen (58%) meniscal tears were located within a rim width of less than 3 mm (red–red zone), whereas 13 (42%) were within a rim width of 3–6 mm (red–white zone). The meniscal tear morphologies were primarily vertical or vertical oblique configurations among the 31 patients. There were 20 right knees (62%) and 11 left knees (38%). The medial meniscus was affected in 20 cases (62%) and the lateral meniscus in 11 cases (38%). The average length of the tears was 27.2 mm (range, 12–35 mm). The number of FasT-Fix anchors used averaged 1.8 (range, 1–3).

At the most recent follow-up, no symptoms of meniscal tears were observed in 30 (96.8%) cases (Fig. 3). One patient (3.2%) reported tenderness on joint-line palpation. No patient had exhibited any locking episodes. Only one case (3.2%) was consid-



**Fig. 3** Magnetic resonance imaging demonstrates a complete healing of the torn lateral meniscus after all-inside meniscal repair with the FasT-Fix meniscal repair system at one year postoperatively (white arrows). The patient had returned to vigorous sports with excellent knee function.

ered a failure. However, no revision arthroscopy was determined to be necessary for this patient. Overall, the Lysholm score increased to a mean value of 90.4 (SD 11), which was statistically significant compared with the preoperative mean value of 65.7 (SD 10) ( $p < 0.0001$ ). Thirty patients (96.8%) had an excellent or good outcome and 1 patient (3.2%) had a fair result. For the 18 patients with isolated meniscal repair, the Lysholm score improved significantly ( $p < 0.0001$ ) from an average of 65 (SD 5) preoperatively to 95 (SD 9) postoperatively. Preoperatively, the mean Tegner activity score was 3.5 (SD 1.5) whereas the postoperative mean value was 6.2 (SD 1.7), which is a statistically significant difference ( $p < 0.0001$ ) (Table 1). For the 13 patients with concurrent ACL reconstruction, the Lysholm score improved significantly ( $p < 0.0001$ ) from an average of 62.3 (SD 10) preoperatively to 88.2 (SD 15) postoperatively. The Tegner activity score also improved significantly ( $p < 0.0001$ ) from an average of 2.7 (SD 1.1) preoperatively to 5.7 (SD 1.2) postoperatively (Table 2). All patients had returned to full-time work.

Complications occurred in 2 out of 31 patients. One patient had a FasT-Fix fixation failure during meniscal repair that was caused by a technical error; this was corrected by refixing with new FasT-Fix instrumentation during the same surgery. One patient had tiny chondral injuries during the fixation procedure. There were no neurovascular or other major complications directly associated with the device.

## DISCUSSION

The blood supply to the meniscus is important to repair and meniscus healing. The peripheral 20-30% of the medial meniscus and the peripheral 10-25% of the lateral meniscus make up the vascular zone.<sup>(18)</sup> However, the inner 1/3 of each meniscus is an avascular zone and is nourished by synovial fluid diffusion. The middle 1/3 zone obtains nourishment from both the blood and synovial fluid. Recent studies have shown that the peripheral blood supply is able to produce a healing response similar to that of other connective tissues. This tissue gradually matures to fibrocartilage over several months following the completed healing process.<sup>(19,20)</sup>

The arthroscopic all-inside technique for meniscal repair has the advantages of less surgical time and ease of performance. This technique has become

**Table 1.** Comparison of Lysholm Knee Scores and Tegner Activity Level in the 18 Patients with Isolated Meniscal Repair Preoperatively and at Final Follow-up

	Preoperatively		Final follow-up*	
	No.	%	No.	%
Lysholm knee score				
Excellent (95-100)	0	0	16	89
Good (84-94)	0	0	2	11
Fair (65-83)	7	39	0	0
Poor (< 65)	11	61	0	0
Mean $\pm$ SD	65 $\pm$ 5		95 $\pm$ 9	
Range	60-72		90-100	
Tegner activity level				
0 to 3	12	67	0	0
4 to 6	6	33	3	17
7 to 10	0	0	15	83
Mean $\pm$ SD	3.5 $\pm$ 1.5		6.2 $\pm$ 1.7	
Range	2-5		5-9	

\*:  $p < 0.05$  (Paired *t* test).

**Table 2.** Comparison of the Lysholm Knee Scores and Tegner Activity Levels for the 13 Patients with Meniscal Repair and Concurrent ACL Reconstruction: Preoperatively and at Final Follow-up

	Preoperatively		Final follow-up*	
	No.	%	No.	%
Lysholm knee score				
Excellent (95-100)	0	0	6	46
Good (84-94)	0	0	6	46
Fair (65-83)	2	15	1	8
Poor (< 65)	11	85	0	0
Mean $\pm$ SD	62.3 $\pm$ 10		88.2 $\pm$ 15	
Range	58 - 70		75 - 100	
Tegner activity level				
0 to 3	10	77	1	8
4 to 6	3	23	5	38
7 to 10	0	0	7	54
Mean $\pm$ SD	2.7 $\pm$ 1.1		5.7 $\pm$ 1.2	
Range	2-5		5-8	

\*:  $p < 0.05$  (Paired *t* test).

the mainstay of recent meniscus repair treatment. There are many kinds of all-inside meniscal repair devices on the market including meniscal arrows, darts, screws, staples, and other suture devices. Jesus et al. have performed an evidence-based review of the outcomes of all-inside meniscal repair devices,<sup>(21)</sup> and the failure rates were found to range from 0% to 43.5%. The success rate for the Meniscus Arrow ranges from 88% to 95%, according to the most recent studies.<sup>(5,22,23)</sup> The healing rate with the T-Fix system has been reported to be nearly 90%.<sup>(24)</sup> Laprell et al. reported a success rate of 86% for the Mitek meniscal repair system.<sup>(25)</sup>

The FasT-Fix device contains two 5-mm Poly-L-Lactide Acid (PLLA) suture T-bar anchors with a pre-tied self-sliding knot comprised of No. 0 nonabsorbable USP braided polyester suture material. Barber et al. used various all-inside meniscal repair devices in adult porcine menisci to compare biomechanical strength.<sup>(12)</sup> Both vertical or horizontal FasT-Fix devices showed the best results compared with the others, including Darts, RapidLoc, and Arthrotek sutures. Borden et al. used cadaver knees to test the biomechanical strength of FasT-Fix and Meniscal Arrows under cyclic loading.<sup>(13)</sup> FasT-Fix completed the cyclic loading with greater strength compared to the Meniscal Arrows. Yavuz et al. also had good results for biomechanical strength when using FasT-Fix in a cadaver study.<sup>(26)</sup> The results described above showed that FasT-Fix had greater strength and durability under cyclic loading compared to the other all-inside repair devices that are currently available. Kotsovolos et al. reported the clinical results of 61 menisci repaired using the FasT-Fix meniscal repair system after an average follow-up period of 18 months.<sup>(27)</sup> The success rate in their series was 90% (55 clinically healed menisci out of 61) according to the criteria of Barrett et al.,<sup>(15)</sup> and 51 patients (88%) had an excellent or good result. Andrew et al. used FasT-Fix for 47 meniscal tears in 37 patients with at least a 2-year follow-up.<sup>(28)</sup> Five of these cases were considered a clinical failure and there were no cases with intra-articular or extra-articular complications such as neurovascular injury. Both prospective studies showed that FasT-Fix is a safe meniscal repair device with a high success rate. In the present series, evaluation of meniscal healing was difficult without magnetic resonance imaging or a secondary arthroscopic evaluation. We acknowledge that a meniscal repair

without symptoms postoperatively does not always reflect the true status of the meniscus and that only second-look by arthroscopy can verify healing of the meniscus or not; this is a limitation of the present study.<sup>(4,5)</sup> However, strict criteria were used to identify a clinical result as a success (joint-line tenderness, McMurray test, effusion). Morgan et al. showed that a clinical examination is a reliable method of evaluating the status of repaired menisci.<sup>(29)</sup> In that study, clinical examination accurately predicted all failures identified by second-look arthroscopy, with no false positives. However, we used strict criteria to consider a clinical result as a success. For example, patients who had occasional soreness or minor symptoms in our study population were classified as failures, although their symptoms were not intense enough as to require revision surgery. The clinical results of the present series were also similar to previous reports. Finally, postoperative Lynsholm and Tegner activity scores had improved significantly compared to preoperative data.

It has been reported that the risk of arthrofibrosis is increased in this type of surgery.<sup>(30)</sup> Ten patients in the present series underwent anterior cruciate ligament reconstruction at the same time as meniscal repair. None have complained of any episode of giving way, difficulty in motion, or unstable knee sensation. These results demonstrate that ACL reconstruction at the time of meniscal repair using the FasT-Fix system is able to achieve successful knee function and stability. However, the principal disadvantages of the present study are the small case number, the lack of a control group and the limited observation period.

There were no complications directly associated with the device in the present series, such as broken implants, synovitis, or migration of the implants, as has been reported for other devices.<sup>(6-8)</sup> Two complications occurred in the second and third patients in the series, but these caused by technical errors (fixation failure and mild chondral injury). This demonstrates that using the FasT-Fix devices has a learning curve. The most important concern associated with the learning curve of this technique was avoiding penetration of the superficial structures including the skin. Premeasurement of the desired depth using a meniscal depth probe is required and should be followed by trimming of the depth-limitation device. Inappropriate use of the instrumentation may prolong

surgical time and result in iatrogenic meniscal or cartilage injury. Therefore, it is important for every surgeon to use the instrument and devices correctly. Arthroscopic all-inside repair with the FasT-Fix device appears to be a safe and effective procedure with a high success rate. There were no neurovascular or other major complications directly associated with the use of the device.

## REFERENCES

1. Annandale T. An operation for displaced semilunar cartilage. *Br Med J* 1885;1:779.
2. Ikeuchi H. Surgery under arthroscopic control. *Proceedings of Societe Internationale Arthroscopie. Rheumatology* 1975;14:57-62.
3. Asik M, Sener N. Failure strength of repair devices versus meniscus suturing techniques. *Knee Surg Sports Traumatol Arthrosc* 2002;10:25-9.
4. Albrecht-Olsen P, Kristensen G, Burgaard P, Joergensen U, Toerholm C. The arrow versus horizontal suture in arthroscopic meniscus repair. *Knee Surg Sports Traumatol Arthrosc* 1999;7:268-73.
5. Albrecht-Olsen P, Kristensen G, Törmälä P. Meniscus bucket-handle fixation with an absorbable Biofix tack: Development of a new technique. *Knee Surg Sports Traumatol Arthrosc* 1993;1:104-6.
6. Anderson K, Marx RG, Hannafin J, Warren RF. Chondral injury following meniscal repair with a biodegradable implant. *Arthroscopy* 2000;16:749-53.
7. Bonshahi AY, Hopgood P, Shepard CJ. Migration of a broken arrow: A case report and review of the literature. *Knee Surg Sports Traumatol Arthrosc* 2004;12:50-1.
8. Calder S, Myers PT. Broken arrow: A complication of meniscal repair. *Arthroscopy* 1999;15:651-2.
9. Arnoczky SP, Lavagnino M. Tensile fixation strengths of absorbable meniscal repairs as a function of hydrolysis time. *Am J Sports Med* 2001;29:118-23.
10. Asik M, Sener N. Failure strength of repair devices versus meniscus suturing techniques. *Knee Surg Sports Traumatol Arthrosc* 2002;10:25-9.
11. McDermott ID, Richards SW, Hallam P, Tavares S, Lavelle JR, Amis AA. A biomechanical study of four different meniscal repair systems, comparing pull-out strengths and gapping under cyclic loading. *Knee Surg Sports Traumatol Arthrosc* 2003;11:23-9.
12. Barber FA, Herbert MA, Richards DP. Load to failure testing of new meniscal repair devices. *Arthroscopy* 2004;20:45-50.
13. Borden P, Nyland J, Caborn DN, Pienkowski D. Biomechanical comparison of the FasT-Fix meniscal repair suture system with vertical mattress sutures and Meniscus Arrows. *Am J Sports Med* 2003;31:374-8.
14. Arnoczky SP, Dodds JA, Wickiewicz TL. Basic Science of the Knee. In: McGinty JB, Caspari RB, Johnson RW, eds. *Operative Arthroscopy*. Philadelphia: Lippincott-Raven, 1996:211-39.
15. Barrett GR, Field MH, Treacy SH, Ruff CG. Clinical results of meniscus repair in patients 40 years and older. *Arthroscopy* 1998;14:824-9.
16. Lysholm J, Gillquist J. Evaluation of knee ligament surgery results with a special emphasis on use of a scoring scale. *Am J Sports Med* 1982;10:150-4.
17. Tegner Y, Lysholm J. Rating system in the evaluation of knee ligament injuries. *Clin Orthop Relat Res* 1986;198:43-9.
18. DeHaven KE. Decision-making factors in the treatment of meniscus lesions. *Clin Orthop Relat Res* 1990;252:49-54.
19. Maitra RS, Miller MD, Johnson DL. Meniscal reconstruction: Part I: Indications, techniques, and graft considerations. *Am J Orthop* 1999;28:213-8.
20. Newman AP, Daniels AU, Burks RT. Principles and decision making in meniscal surgery. *Arthroscopy* 1993;9:33-51.
21. Jesus L, Benjamin M, Dilworth C. All inside meniscus repair: A systemic review. *Clin Orthop Relat Res* 2006;455:134-41.
22. Gill SS, Diduch DR. Outcomes after meniscal repair using the Meniscus Arrow in knees undergoing concurrent anterior cruciate ligament reconstruction. *Arthroscopy* 2002;18:569-77.
23. Huerel C, Mertens F, Verdonk R. Biofix resorbable Meniscus Arrow for meniscal ruptures: Results of a 1-year follow-up. *Knee Surg Sports Traumatol Arthrosc* 2000;8:46-52.
24. Asik M, Sen C, Erginsu M. Arthroscopic meniscal repair using T-fix. *Knee Surg Sports Traumatol Arthrosc* 2002;10:284-8.
25. Laprell H, Stein V, Petersen W. Arthroscopic all-inside meniscus repair using a new refixation device: A prospective study. *Arthroscopy* 2002;18:387-93.
26. Yavuz K, Haw CC, David N. A biomechanical comparison of the Fast-Fix meniscal repair system and the RapidLoc device in cadaver meniscus. *Arthroscopy* 2006;22:406-13.
27. Kotsovolos ES, Hantes ME, Mastrokalos DS. Results of all-inside meniscal repair with the FasT-Fix meniscal repair system. *Arthroscopy* 2006;22:3-9.
28. Andrew L, Anthony A, Joshua H. Meniscal repair using FasT-Fix all-inside meniscal devices. *Arthroscopy* 2005;21:167-75.
29. Morgan CD, Wojtys EM, Casscells CD, Casscells SW. Arthroscopic meniscal repair evaluated by second look arthroscopy. *Am J Sports Med* 1991;19:632-8.
30. Austin KS, Sherman OH. Complications of arthroscopic meniscal repair. *Am J Sports Med* 1990;21:864-9.

# 利用全膝關節鏡內 (all-inside) 半月板修補器 FasT-Fix 治療半月板受損的臨床成果

姜智偉 張宗訓 程俊穎 陳昭宇 詹益聖 徐郭堯 陳文哲

- 背景：**半月板在膝關節功能中扮演很重要的角色，而半月板修復是針對半月板受損的主要治療方式。相較於開放手術，膝關節鏡半月板修復手術因為耗時短，傷口小和易接近受傷部位而受歡迎。目前有三種關節鏡手術技術被廣泛應用：inside-out、outside-in、和 all-inside。而其中又以全膝關節鏡內 (all-inside) 修復手術之神經血管損傷率最低。
- 方法：**本研究使用前瞻式評估方法追蹤 31 位病人接受治療來探討 FasT-Fix 對於膝關節鏡半月板修復手術的影響力及安全性。31 位病人篩選的準則包含 (1) 垂直且整層破裂撕裂傷長度大於 10 mm，(2) 半月板撕裂傷距離 meniscocapsular 交界處小於 6 mm，(3) 只使用全膝關節鏡內 FasT-Fix 系統修復半月板損傷，(4) 未接受近一步的半月板修復手術 (5) 在接受關節鏡手術期間沒有關節炎的跡象。若膝關節病變合併前十字韌帶缺損，則手術治療半月板後同時使用病人自身之 hamstring tendon 重建其前十字韌帶。術後於每次回診使用 Lysholm knee score 和 Tegner activity score 追蹤紀錄膝關節功能。
- 結果：**最新的術後追蹤，在 30 (96.8%) 位病人中並未發現半月板再撕裂的症狀。而對於接受單獨半月板修復或合併前十字韌帶的病人而言，其 Lysholm 和 Tegner activity scores 在統計上有明顯的改善 ( $p < .05$ )。所有病人並未發現有神經血管的受損或其他因使用 FasT-Fix 裝置所造成的重大併發症。
- 結論：**研究結果顯示使用膝關節鏡 all-inside 之 FasT-Fix 修補裝置治療半月板受損為一有效且安全的方法。  
(長庚醫誌 2011;34:298-305)

**關鍵詞：**半月板撕裂，關節鏡，全膝關節鏡內半月板修補

---

長庚醫療財團法人林口長庚紀念醫院 骨科部 運動醫學科；長庚大學 醫學院

受文日期：民國99年4月22日；接受刊載：民國99年11月18日

通訊作者：詹益聖醫師，長庚醫療財團法人林口長庚紀念醫院 骨科部 運動醫學科。桃園縣333龜山鄉復興街5號。

Tel.: (03)3281200轉3882; Fax: (03)3278113; E-mail: chan512@adm.cgmh.org.tw