

## An Anatomical Study of the Inferior Oblique Muscle with Emphasis on Its Nerve Entry

Vishal Kumar, MD; B.V. Murlimanju<sup>1</sup>, MD; P. Devika<sup>2</sup>, DNB; Narga Nair<sup>3</sup>, MS; Shakuntala R. Pai<sup>3</sup>, MS; Thejodhar Pulakunta<sup>4</sup>, MD; N.S. Naveen<sup>5</sup>, MD

**Background:** Anatomical studies regarding the inferior oblique muscle are scarce and the exact location of the entry of oculomotor nerve to the muscle has not been reported. In the present study, the objectives were to examine the exact location of the entry of oculomotor nerve to the inferior oblique muscle and to study the topographical anatomy of the muscle.

**Methods:** The study included 56 intact orbits from 28 embalmed south Indian adult cadavers. The entire course of the nerve to the inferior oblique was exposed from both anterior and posterior aspects in all specimens. The exact location of the entry of nerve supplying the inferior oblique muscle was identified and the distances of the muscle from inferior and medial orbital margins were measured.

**Results:** The oculomotor nerve entered the inferior oblique muscle through the orbital surface in 42 (75%) cases, through the ocular surface in 10 (17.9%) cases and through the posterior border in 4 (7.1%) cases. The distance of the muscle from the inferior orbital margin was 1 mm in majority (78.5%) of the cases. The distance of the muscle from the medial orbital margin was 11 mm in majority (42.8%) of the cases.

**Conclusion:** The present study reports that the oculomotor nerve most often enters the inferior oblique muscle through its orbital surface. Detailed knowledge of the topographical anatomy of inferior oblique muscle and its site of nerve entry are essential for surgeons when performing ophthalmological surgery and regional anesthesia.

(*Chang Gung Med J 2011;34:293-7*)

**Key words:** oculomotor nerve, inferior oblique, orbit, muscle, anatomy

The inferior oblique is a thin, narrow muscle near the anterior margin of the floor of the orbit. It arises from the orbital surface of the maxilla just lateral to the nasolacrimal groove.<sup>(1)</sup> The tendon is inserted into the lateral side of the sclera under the cover of the lateral rectus and close to the insertion

of the superior oblique. The muscle receives its nerve supply from the inferior division of the oculomotor nerve, which runs forward between the inferior and lateral rectus muscles and also provides the parasympathetic root to the ciliary ganglion.<sup>(2)</sup> The nerve to inferior oblique is the longest branch of the

From the Department of Anatomy; <sup>2</sup>Department of Ophthalmology, K.S. Hegde Medical Academy, Nitte University, Mangalore, India; <sup>1</sup>Department of Anatomy, Kasturba Medical College, Manipal University, Mangalore, India; <sup>3</sup>Department of Anatomy, Kasturba Medical College, Manipal University, Manipal, India; <sup>4</sup>Department of Anatomy, St. Matthew's University School of Medicine, Grand Cayman Islands, British West Indies; <sup>5</sup>Department of Anatomy, K. M. C. T. Medical College, Calicut University, Calicut, India.

Received: May 3, 2010; Accepted: Oct. 29, 2010

Correspondence to: Prof. B.V. Murlimanju, Department of Anatomy, Kasturba Medical College, Manipal University, Mangalore, India. Bejai, Mangalore – 575004, India. Tel.: +91-824-2211746; Fax: +91-824-2421283; E-Mail: flutesnowmm@gmail.com

inferior division of the oculomotor nerve, which enters the muscle through its orbital surface.<sup>(1)</sup> However there exists controversy regarding the site of nerve entry to this muscle. Some authors indicate that the nerve enters through its posterior border, while others have the opinion that the nerve enters through the ocular surface. This can be explained by the fact that the anatomy of cranial nerves is complex; nevertheless, the evaluation of patients with cranial neuropathies requires an in-depth understanding of the normal course of these important structures.<sup>(3)</sup> A detailed knowledge of the site of nerve entry to the inferior oblique muscle and the topographical anatomy of the muscle is necessary for a surgeon when performing ophthalmological surgery and regional anesthesia. However, studies related to the site of entry of oculomotor nerve to the muscle have not been reported hitherto. Hence the present investigation was undertaken, which places emphasis on the entry of oculomotor nerve to the inferior oblique muscle. The objectives of the present study were to assess the exact location of the entry of oculomotor nerve to the muscle and to study the topographical anatomy of the inferior oblique muscle.

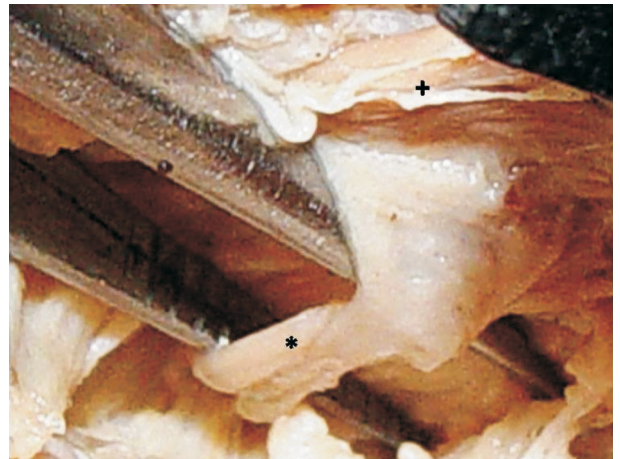
## METHODS

The study included 56 intact orbits from 28 (21 male and 7 female) embalmed south Indian adult cadavers that were obtained from the anatomy laboratory. The specimens have been preserved in 10% formaldehyde solution. The orbital roofs were removed systematically to expose the structures within the orbits. Both the right and left orbits were exposed and the entire course of the nerve to the inferior oblique was exposed from both anterior and posterior aspects. In the present study, the superior surface of the muscle was named the ocular surface and the inferior surface was named the orbital surface. The muscle is normally described as having the anterior and posterior borders near its insertion. The exact location of the entry of oculomotor nerve to the inferior oblique muscle with respect to these surfaces and borders were identified in all specimens. The distance of the muscle from the inferior and medial orbital margins were also studied. The distances were measured from the anterior lacrimal crest, which is present in the medial orbital margin and the inferior orbital rim just above the infraorbital foramen.

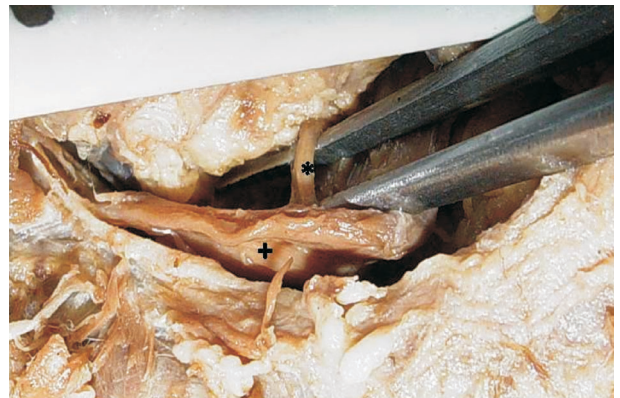The measurements were taken with the help of a Vernier caliper of 2 mm accuracy.

## RESULTS

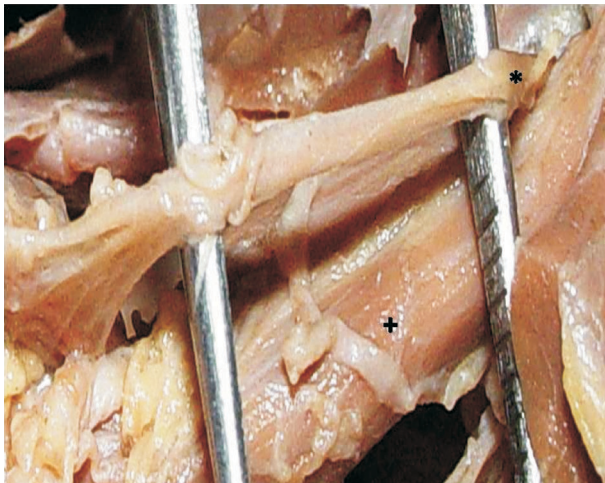
The oculomotor nerve was found to enter the inferior oblique muscle through the orbital surface (inferior surface) in 42 (75%) cases (Fig. 1), through its ocular surface (superior surface) in 10 (17.9%) cases and through the posterior border (Fig. 2), near the insertion, in 4 (7.1%) cases (Fig. 3). The distance of the muscle from the inferior orbital rim just above the infraorbital foramen was 1mm in 44 (78.5%) cases, 3 mm in 4 (7.2%) cases and 4 mm in the



**Fig. 1** Photograph taken at the front of the face showing the oculomotor nerve (\*) entering the inferior oblique muscle (+) through its orbital surface.



**Fig. 2** Photograph taken at the front of the face showing the oculomotor nerve (\*) entering the inferior oblique muscle (+) through its ocular surface.



**Fig. 3** Photograph taken at the front of the face showing the oculomotor nerve (\*) entering the inferior oblique muscle (+) through its posterior border.

remaining 8 (14.3%) cases. The distance of the muscle from the anterior lacrimal crest of medial orbital margin was 11 mm in 24 (42.8%) cases, 12 mm in 14 (25%) cases, 9 mm in 9 (16.1%) cases and 10 mm in the remaining 9 (16.1%) cases.

## DISCUSSION

Knowledge of the topographical anatomy of entry of oculomotor nerve to inferior oblique muscle is very important, since this muscle is one that is commonly operated on in squint surgery. The inferior oblique muscle is the shortest of all the eye muscles, being only 37 mm long. It arises in the anteroinferior angle of the bony orbit in a shallow depression in the orbital plate of the maxilla near the lateral edge of the entrance to the nasolacrimal canal.<sup>(4)</sup> The muscle originates on the orbital floor, about 5 mm posterior to the inferior orbital rim, on a line extending from the infraorbital foramen to the supraorbital notch.<sup>(5)</sup> The muscle continues from its origin backwards, upwards, and laterally and passes between the floor of the orbit and the inferior rectus muscle. It is described as having orbital and ocular surfaces, of which the orbital surface lies inferiorly and the ocular surface lies superiorly. It inserts via a short tendon (1 to 2 mm) in the posterior and external aspect of the sclera.<sup>(4)</sup> The width of the muscle at insertion varies from 5 to 14 mm and seems to be around 9

mm on average.<sup>(6)</sup> The insertion forms a curved concave line toward the origin of the muscle. The muscle is described usually as having the anterior and posterior borders near its insertion. Its anterior border is about 10 mm behind the lower edge of the insertion of the lateral rectus muscle and its posterior border is 1 mm below and 1 to 2 mm in front of the macula. Near its insertion, the posterior border of the inferior oblique muscle is related to the inferior vortex vein.<sup>(4)</sup> The muscle receives its vascular supply by a medial muscular branch of the ophthalmic artery and a branch of the infraorbital artery. It is drained by the inferior orbital vein.<sup>(7)</sup> The muscle has been described as being derived from prechordal mesoderm.<sup>(8)</sup> Unlike the other extraocular muscles, especially the superior obliques, which have both muscular and tendinous components, the inferior oblique is almost entirely muscular.<sup>(4)</sup>

Surgery in this area has undergone significant changes in the past 160 years and the recent anatomical studies have greatly helped surgeons to solve vertical strabismus problems.<sup>(9)</sup> In this context, modern surgical procedures, including anesthesia, require a more precise understanding of the surrounding anatomy. According to Standring,<sup>(1)</sup> the oculomotor nerve enters the inferior oblique muscle through its orbital surface. In contrast, Wolff reports that the nerve enters the inferior oblique through its ocular surface.<sup>(10)</sup> In the present study, we agree in general with Standring because we observed that the nerve entered the inferior oblique through its orbital surface in the majority (75%) of our specimens.<sup>(1)</sup>

Ophthalmologists should know the complete anatomy of the muscle before beginning any surgical procedure. The topographical anatomy and the site of nerve entry of inferior oblique are thus of utmost important. In the present study, we observed that the distance of the muscle from the inferior orbital margin just above the infraorbital foramen was 1 mm in the majority (78.5%) of the cases and the distance of the muscle from the anterior lacrimal crest of medial orbital margin was 11 mm in the majority (42.8%) of the cases. The anterior lacrimal crest forms the anterior boundary of the lacrimal fossa, which is formed by frontal process of the maxilla and the lacrimal bone. These features are present on the medial wall of the orbit.<sup>(11)</sup> The inferior orbital margin is raised slightly above the floor of the orbit. It is formed by the zygomatic bone and the maxilla, usually in equal

portions. The inferior orbital margin is clearly defined on its outer aspect and is readily palpated. This part of the inferior orbital rim is often fractured in accidents producing associated disruption of the inferior oblique muscle and subsequent diplopia.<sup>(11)</sup> It has been reported that the origin of the inferior oblique muscle is found 9.4 mm lateral to the medial canthus.<sup>(12)</sup> The findings of the present study agrees well this report regarding the distance of the muscle from the medial orbital margin.

Since injury to this muscle remains as an infrequent but potentially debilitating complication, we investigated the cadaveric specimens in the present study to establish the site of nerve entry and to delineate the location of the inferior oblique muscle, which could then serve as a guide for avoiding inadvertent injury to this muscle. Injury to the inferior oblique muscle can result in symptoms ranging from transient diplopia to a more debilitating permanent strabismus. It has been reported that precise knowledge of the anatomy and the use of proper techniques are recommended to avoid this type of injury.<sup>(13)</sup> Delineating the location of the inferior oblique muscle before making any incision is also critical to avoid injury to the muscle.<sup>(14)</sup> Anterior transposition of the inferior oblique muscle has been done for the patients with inferior oblique overaction, especially in the presence of a dissociated vertical deviation and fourth nerve palsy.<sup>(15)</sup> It has been reported that contraction of the inferior oblique, which has no tendon and is muscular up to its insertion, pulls on the rather thin sclera of a high myope and this can result in a predisposition to the formation of a tear or hole in the retina.<sup>(16)</sup> The muscle's overaction may cause a socially noticeable vertical hypertropia of the affected eye in the primary position and in a contralateral gaze.<sup>(17)</sup> Thus an inferior oblique myotomy could be suggested as a prophylactic measure to prevent the formation of tears or holes and to prevent recurrences.<sup>(16)</sup> The most commonly carried out surgeries on the inferior oblique include myectomy, recession and anterior transposition.<sup>(18)</sup> The collapsing of the anterior and posterior borders of the recessed inferior oblique muscle while suturing it to the sclera has been described as enhancing the weakening effect of surgery done to correct a squint.<sup>(19)</sup> The inferior oblique muscle has been recently highlighted in the Grave's orbitopathy.<sup>(20)</sup> This muscle is also preferred for use in biopsy studies of the extraocular mus-

cles.<sup>(21)</sup> It has been reported that, since the inferior oblique muscle is situated in a crowded area that includes the inferior rectus muscle and the globe, it is sometimes difficult to study this muscle even with high resolution MRI. In these circumstances, anatomical studies using cadavers are a reliable reference for clinicians.<sup>(20)</sup>

## Conclusion

Anatomical studies regarding the inferior oblique muscle are rare and hence the present investigation was undertaken with reference to the muscle's surgical significance. The exact location of the entry of the oculomotor nerve to the inferior oblique muscle was assessed. In majority of our specimens (75%), the oculomotor nerve entered the inferior oblique muscle through its orbital surface. In addition, the distances of the muscle from the important bony landmarks have been noted, which are important when carrying out surgery in this region. These details are important not only to ophthalmologists but also to oral and maxillo facial surgeons, neurosurgeons and plastic surgeons. We believe that this study provides reliable additional information on the topographical anatomy and neuroanatomy of the inferior oblique, which will be useful not only to surgeons and anesthesiologists, but also to anatomists and morphologists.

## REFERENCES

1. Gray's Anatomy. The Anatomical Basis of Clinical Practice. In: Standring S, ed. 39th ed. Edinburgh: Churchill Livingstone, 2006:694.
2. Romanes GJ. Cunningham's Manual of Practical Anatomy. 15th ed. vol 3. Oxford Medical Publications, 2005:112-3.
3. Sheth S, Branstetter IV BF, Escott EJ. Appearance of normal cranial nerves on steady-state free precession MR images. *Radiographics* 2009;29:1045-55.
4. von Noorden GK, Campos EC. Binocular vision and ocular motility; theory and management of strabismus. 6th ed. St. Louis: Mosby, 2002:44.
5. Mowlavi A, Neumeister MW, Wilhelmi BJ. Lower blepharoplasty using bony anatomical landmarks to identify and avoid injury to the inferior oblique muscle. *Plast Reconstr Surg* 2002;110:1318-22.
6. Fink WH. Surgery of the vertical muscles of the eyes. 2nd ed. Springfield, IL: Charles C Thomas, 1962.
7. Isenberg SJ, Apt L. Inferior oblique weakening procedures: technique and indications. In: Rosenbaum AL,

- Santiago AP, eds. Clinical strabismus management, principles and surgical techniques. Philadelphia: W.B. Saunders Company, 1999:449-58.
8. Szekely G. Comparative anatomy of cranial nerve motor nuclei: with a comment on evolution of the craniofacial region. *Europ J Morphol* 1994;32:217-24.
  9. Stager D. Anatomy and surgery of the inferior oblique muscle: Recent findings. *J AAPOS* 2001;5:203-8.
  10. Wolff E. *The Anatomy of the Eye and Orbit*. 4th ed. London: Lewis, 1954:231.
  11. Patnaik VVG, Sanju B, Singla RK. Anatomy of the bony orbit-some applied aspects. *J Anat Soc India* 2001;50:59-67.
  12. Yousif NJ, Sonderman P, Dzwierzynski WW, Larson DL. Anatomic considerations in transconjunctival blepharoplasty. *Plast Reconstr Surg* 1995;96:1271.
  13. Seiff SR. Complications of upper and lower blepharoplasty. *Int Ophthalmol Clin* 1992;32:67.
  14. Mowlavi A, Neumeister MW, Wilhelmi BJ. Lower blepharoplasty using bony anatomical landmarks to identify and avoid injury to the inferior oblique muscle. *Plast Reconstr Surg* 2002;110:1318-22.
  15. Aguirre-Aquino BI, Riemann CD, Lewis H, Traboulsi EI. Anterior transposition of the inferior oblique muscle as the initial treatment of a snapped inferior rectus muscle. *J AAPOS* 2001;5:52-4.
  16. El Massri A. Relation of macular and other holes to the insertion of the inferior oblique. *Br J Ophthalmol* 1963;47:90-4.
  17. Shipman T, Burke J. Unilateral inferior oblique muscle myectomy and recession in the treatment of inferior oblique muscle overaction: a longitudinal study. *Eye* 2003;17:1013-8.
  18. Min BM, Park JH, Kim SY, Lee SB. Comparison of inferior oblique muscle weakening by anterior transposition or myectomy: a prospective study of 20 cases. *Br J Ophthalmol* 1999;83:206-8.
  19. Apt L, Call NB. Inferior oblique muscle recession. *Am J Ophthalmol* 1978;85:95.
  20. Takahashi Y, Kakizaki H, Nakano T, Asamoto K, Iwaki M. Inferior oblique muscle thickness in Asians. *Clinical Ophthalmology* 2008;2:299-302.
  21. Hoogenraad TU, Tan KEWP, Eelderink HJW, Veldman H, Jennekens FGI. The inferior oblique as muscle of choice for biopsies of extraocular muscles. *Br J Ophthalmol* 1979;63:680-3.