

Open and Arthroscopic Surgical Management of Primary Synovial Chondromatosis of the Hip

Yi-Hsun Yu, MD; Yi-Sheng Chan, MD; Mel S. Lee, MD, PhD; Hsin-Nung Shih, MD

Background: Primary synovial chondromatosis commonly involves large joints such as the knee and hip. The optimal approaches for successful surgical management of symptomatic primary synovial chondromatosis of the hip joint are controversial.

Methods: The current study reviewed 9 patients with primary synovial chondromatosis of the hip who underwent surgical treatment between 2000 and 2005. By identification of the surgical indications, we chose the optimal surgical approach, open arthrotomy or arthroscopic surgery, for a definite treatment.

Results: Of the 9 patients, 4 underwent open arthrotomy and 5 underwent hip arthroscopic surgery. The mean follow-up duration was 24.9 months (range, 12–50). There were no perioperative or postoperative complications. There was 1 recurrence 2 years after the first arthroscopic surgery. All hips remained in stationary condition on radiological follow-up except for 1 hip, the recurrence case. The mean Harris Hip Score at the 12-month follow-up was 93.7 (range, 90–99).

Conclusions: Surgical treatment for primary synovial chondromatosis of the hip proved beneficial for these patients. By means of identified indications, selecting an appropriate surgical approach provides a rapid recovery and low incidence of recurrence.

(Chang Gung Med J 2011;34:101-8)

Key words: synovial chondromatosis, arthrotomy, arthroscopy

Primary synovial chondromatosis (PSC) is a rare and benign disease characterized by multi-nodular cartilaginous proliferation in the synovium of the joint, tendon sheath or bursa.^(1,2) This disease is thought to be a metaplasia and is usually self-limiting.⁽³⁾ Synovial chondromatosis has a predilection for major joints. The knee joint has the highest prevalence of this disease followed by the hip joint.⁽²⁾

Patients with PSC of the hip usually present in the second to fifth decades. Typical symptoms of

PSC of the hip include pain, antalgic gait, locking, and a restricted range of motion. Since clinical symptoms of PSC of the hip are usually insidious and nonspecific, detection of the disease at an early stage may be difficult. When the disease has been diagnosed, it is most often symptomatic with radiographic evidence of loose bodies which have likely been present for several years. Therefore, certain complications can occur.

The optimal approaches for the successful surgi-

From the Division of Joint Reconstruction, Department of Orthopedic Surgery, Chang Gung Memorial Hospital at Linkou, Chang Gung University College of Medicine, Taoyuan, Taiwan.

Received: Apr. 12, 2010; Accepted: Jul. 16, 2010

Correspondence to: Dr. Hsin-Nung Shih, Division of Joint Reconstruction, Department of Orthopedic Surgery, Chang Gung Memorial Hospital at Linkou, 5, Fusing St., Gueishan Township, Taoyuan County 333, Taiwan (R.O.C.)

Tel.: 886-3-3281200 ext. 2420; Fax: 886-3-3274564; E-mail: aronc@cgmh.org.tw

cal management of symptomatic PSC of the hip joint are controversial. Open arthrotomy with hip dislocation provides adequate debridement, removal of all loose bodies, and near-total synovectomy. Some investigators have suggested that arthroscopy of the hip avoids the considerable surgical exposure and prolonged rehabilitation associated with open hip arthrotomy and synovectomy.⁽⁴⁻⁶⁾ However, inadequate debridement and a relatively high recurrence rate are the major concerns. The present study aimed to identify the optimal surgical approach for PSC of the hip by reviewing patients who underwent surgical treatment. We hypothesized that selecting an appropriate surgical approach based on specific indications outlined in the present study would help to optimize outcomes in this patient population.

METHODS

We reviewed retrospectively patients treated surgically for symptomatic PSC of the hip joint from August 2000 to October 2005 at Chang Gung Memorial Hospital. Indications for surgery were failure of conservative treatment for more than 6 weeks, progressive hip joint deformity, and progressive hip degenerative osteoarthritic changes resulting from intraarticular osteochondral fragments.

The following patient data were recorded prospectively and analyzed retrospectively; age, gender, affected side, symptoms, size and location of loose bodies, operative procedures, duration of follow-up, and pre- and postoperative osteoarthritic changes in the hip. Prior to surgical intervention, plain radiographs of the affected hip in the standard pelvic anteroposterior and true lateral views were acquired for all patients. Degeneration of the hip was assessed before surgery and at the last follow-up according to the grading system described by Kellgren and Lawrence.⁽⁷⁾ Computed tomography (CT) or magnetic resonance imaging (MRI) studies were performed routinely according to the clinical decisions of the surgeons.

All patients underwent either an open arthrotomy or arthroscopic surgery for definite treatment. Indications for open arthrotomy were large loose bodies measured from imaging studies (more than 1 cm x 1 cm), previous surgery on the affected hip, and extraarticular presentation on imaging study. Indications for arthroscopic surgery were uncertain

diagnosis of the hip lesion, single or small number of loose bodies, and need for a rapid return to daily activity.

In the open arthrotomy group, hip joint dislocation was not performed in any patient during surgery. Surgery was performed by the anterolateral transgluteal approach described by Hardinge.⁽⁸⁾ Complete removal of loose bodies and near-total synovectomy were performed.

In the hip arthroscopic surgery group, patients were placed in the supine position on a fracture table.^(9,10) Traction of the involved limb at 25° adduction was performed under fluoroscopic assistance. A blunt trochar was placed into the hip joint after a sequential dilatation of the tract. An arthroscope with a protecting sheath was inserted and the hip joint was examined. As many loose bodies as possible were removed. Additionally, a partial synovectomy was performed. The size and number of loose bodies removed from the joint were recorded. All specimens obtained from the surgeries were examined by experienced pathologists.

All patients received a one-day course of treatment with prophylactic first-generation cephalosporins. No agreement on the necessity for prophylactic procedures for potential complications such as heterotopic ossification and thromboembolism in these patients was made in our institution. After surgery, all patients were permitted to ambulate with the assistance of a crutch or walker. They were discharged after they were capable of independent ambulation and could return to daily life. We used plain radiographs for radiological outcome assessment and the Harris Hip Score (HHS) for functional outcome evaluation at the 12-month clinic follow-up.

RESULTS

We retrospectively reviewed 9 patients treated for symptomatic PSC of the hip between 2000 and 2005. Their clinical data is listed in Table 1. Seven of the 9 patients were men and five cases involved the right hip. The largest loose body found in open surgery was 110 mm (Fig. 1) and in arthroscopic surgery, 10 mm (Fig. 2).

By identification of the indications, 4 patients underwent open arthrotomy and 5 underwent an arthroscopic procedure for the removal of loose bodies. Near-total or partial synovectomy was performed

Table 1. Clinical Data of 9 Patients Treated for Primary Synovial Chondromatosis

No	Gender	Age	Side	Symptoms	Interval between symptoms & surgical treatment (months)	PreOP OA grading	Additional imaging	Location	Max. size and numbers of loose bodies	Operative procedure	Follow-Up (months)	Recurrence	PostOP OA grading	Hospital stay (days)	HHS
1	Male	70	Right	Groin pain Flexion contracture	60	2	CT	Anterior	40 mm Multiple	Arthroscopy	12	No	2	10	92
2	Male	60	Right	Groin pain Limping	24	2	MRI	Anterior & Posteroinferior	8 mm Multiple	Arthroscopy	34	Yes	3	8	90
3	Male	44	Left	Groin pain Limping	36	3	MRI	Anterior	10 mm Multiple	Arthroscopy	16	No	3	5	96
4	Male	32	Right	Groin pain Locking	26	1	MRI	Anteroinferior	5 mm Multiple	Arthroscopy	12	No	1	5	99
5	Male	22	Left	Groin pain Limping	24	2	MRI	Anterior	9 mm multiple	Arthroscopy	13	No	2	3	92
6	Female	47	Left	Groin pain Limping	36	2	CT	Anterior & Posteroinferior	25 mm Multiple	Arthroscopy	13	No	2	10	90
7	Female	59	Left	Groin pain ROM limitation	30	3	MRI	Anteroinferior & Posteroinferior	10 mm Multiple	Arthroscopy	40	No	3	3	96
8	Male	55	Right	Groin pain Limping	60	2	CT	Posterolateral & Posteroinferior	20 mm Multiple	Arthroscopy	50	No	2	7	99
9	Male	72	Right	Groin pain Limping	30	2	MRI	Anteroinferior	110 mm Multiple	Arthroscopy	21	No	2	5	90

Abbreviations: PreOp: preoperation; OA: osteoarthritis; PostOP: postoperation; HHS: Harris Hip Score; ROM: Range of motion.

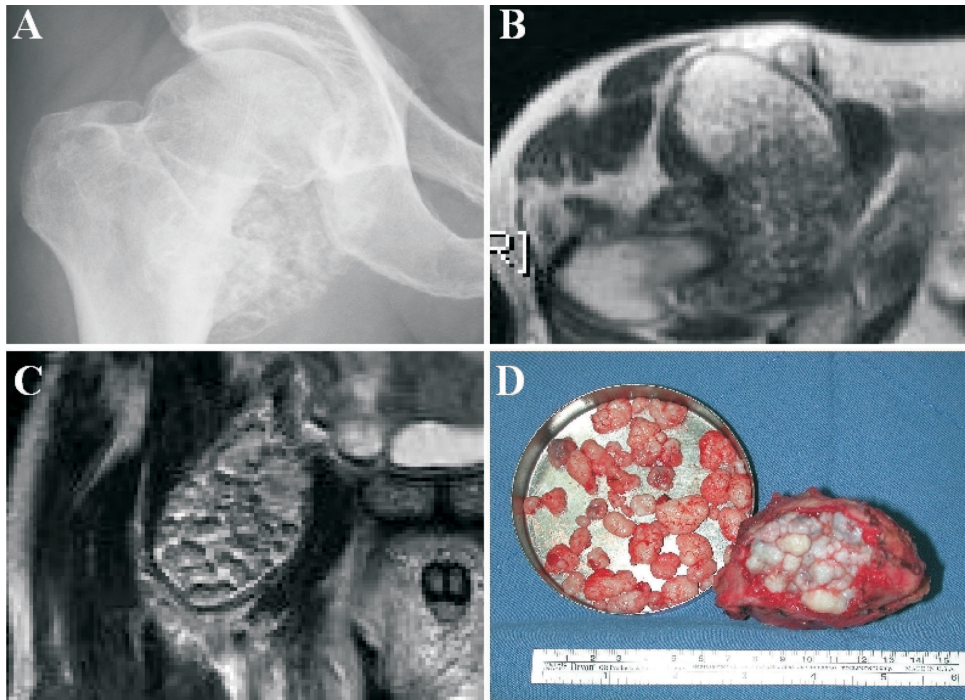


Fig. 1 A 72-year-old man presented with synovial chondromatosis of the right hip. (A) Pelvic anteroposterior plain radiograph. (B) and (C) Magnetic Resonance Imaging (D) Gross pathology.

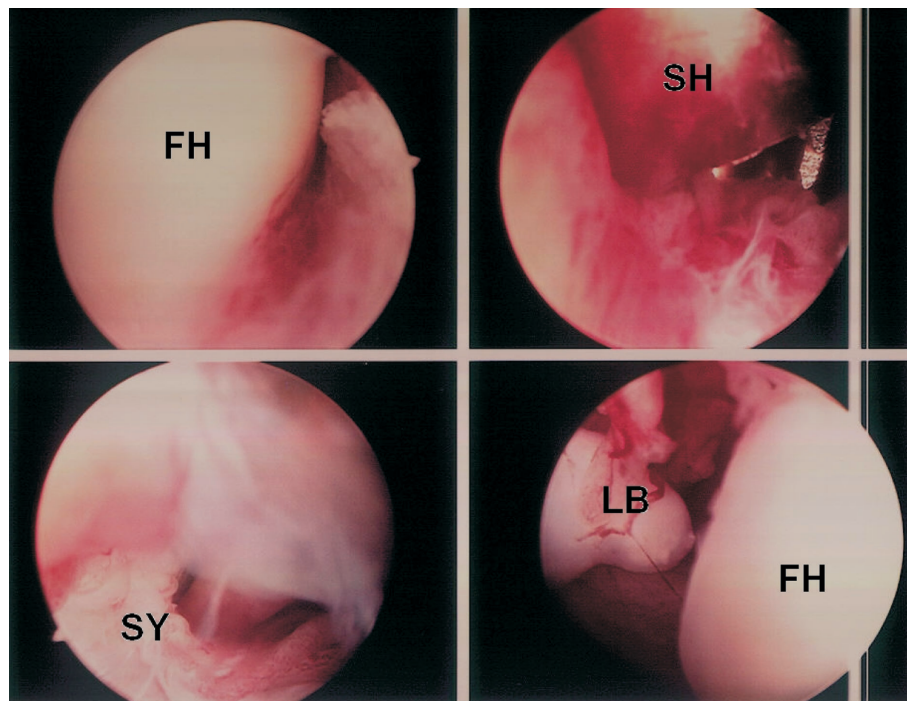


Fig. 2 Hip arthroscopic surgery for synovial chondromatosis of the hip. Abbreviations: FH: femoral head; LB: loose body; SH: sheath for instrumentation; SY: synovium.

in all patients. There were no complications during the hospital stay. In 1 patient (patient no. 2), recurrence was observed 2 years after the first arthroscopic surgery; this patient underwent open arthrotomy at the second surgery. He was disease-free at the last clinical follow-up. One patient (patient no. 7) was symptom-free at the last clinic follow-up after the arthroscopic surgery despite inadequate removal of loose bodies. All patients were followed up at least 12 months (mean: 24.9; range: 12–50).

The radiological and functional outcomes were evaluated at the 12-month clinic follow-up. According to the grading system of Kellgren and Lawrence for osteoarthritis, all hips remained in stationary condition after the index surgery compared with preoperation except for 1 patient (no. 2), the recurrence case. The mean HHS for evaluation of functional outcome was 93.7 (range, 90–99).

DISCUSSION

In general, preoperative evaluation for PSC of

the hip includes the clinical history, physical examination, family history of cancer, and, most importantly, imaging studies. Patients may have dull aching pain in the hip, a locking sensation, crepitation, and restriction of motion. Plain radiographs are always the initial study. Loose bodies are not present on plain radiographs unless there is ossification.^(10,11) Therefore, accurate diagnosis of PSC of the hip joint is often delayed. Whether loose bodies are present on radiography or not, a CT scan or MRI study is the next examination. In addition to good resolution of the tumor mass in both studies, the connection with the surrounding tissue is also an important reason to perform these advanced studies. Once these delicate image studies are performed and interpreted, a surgical intervention is chosen which will ensure adequate debridement and a low rate of recurrence.

Several clinical studies of the management of PSC of hip have been published in recent decades (Table 2). However, there is still controversy in the literature on the treatment of PSC. The choices include conservative or operative treatment, open or

Table 2. Clinical Studies of Surgical Approaches for Primary Synovial Chondromatosis of the Hip

Study	Number of cases	Surgical technique	Surgical dislocation	Conclusions
Okada 1989	1	Arthroscopy	No	A case report of arthroscopic surgery for PSC of the hip.
Ganz 2000		Arthrotomy	Yes	A technique of surgical dislocation of the hip joint without increasing the incidence of AVNFB.
Krebs 2003	–	Arthroscopy	–	1. The minimally-invasive nature and low morbidity associated with hip arthroscopy make it ideal for establishing an early preventive strategy to treat symptomatic patients with loose bodies in the hip. 2. Progression and recurrence of disease cannot be predicted with current knowledge.
Chen 2003	2	Arthroscopy	No	A Two case reports of PSC of the hip with arthroscopy-assisted synovectomy and removal of loose bodies.
Lim 2006	21	Arthrotomy	Yes	1. Open synovectomy and removal of loose bodies is a reliable procedure for PSC of the hip. 2. PSC may recur in patients with extensive involvement who are treated with synovectomy alone without dislocation.
Schoeniger 2006	6	Arthrotomy	Yes	1. Open debridement with a modified total synovectomy is an effective treatment. 2. Surgical hip dislocation allows safe and complete access to the joint with no added morbidity.
Boyer 2008	111	Arthroscopy	No	Hip arthroscopy proved beneficial for patients diagnosed with PSC of the hip, providing good or excellent outcomes in more than half cases.

Abbreviation: PSC: primary synovial chondromatosis.

arthroscopic surgery, whether to use a surgical dislocation in open surgery and whether a synovectomy is needed. However, there is no study comparing all these controversies. Both open and arthroscopic surgeries were performed for PSC of the hip and satisfactory outcomes were achieved in each study. However, each study was conducted by a single surgical approach. A critical point of the current study was to define the indications and choose an appropriate surgery for patients with different clinical presentations. Thus, our results showed successful clinical results, with both physical and personal satisfaction and excellent radiological and functional outcomes. In our series, arthrotomy was performed without surgical dislocation of the hip. Intraoperatively, manual traction of the hip with copious irrigation with normal saline was performed. The purpose was to remove all intraarticular loose bodies and perform as complete a synovectomy as possible without complications from hip dislocation, such as osteonecrosis of the femoral head and fracture of the femoral neck.^(12,13) Additionally, less extensive surgery allows early rehabilitation. All 4 patients with arthrotomy in the current study were able to walk within 1 or 2 days after surgery.

Hip arthroscopy is a method of examination and diagnosis of hip lesions in the event of persistent hip symptoms and lack of radiographic evidence, as well as simultaneously providing treatment.^(5,14) However, the major concern of hip arthroscopy is insufficient observation and inadequate debridement with a high recurrence rate.⁽¹²⁾ The standard entry ports for hip arthroscopy are anterior, anterolateral, and posterolateral ports.^(9,15) The posterior capsule and pouch are difficult to access by the arthroscope because the working space is small and the sciatic nerve is potentially jeopardized. An unavoidable drawback of hip arthroscopy is the lack of sufficient observation to perform an adequate synovectomy and complete removal of loose bodies, especially when a posteroinferior approach is used.⁽¹⁶⁾

In our series, 5 patients underwent arthroscopic surgery. All extracted loose bodies were located mainly in the anterior pouch of the hip joint. One patient experienced a recurrence 2 years after the surgery and underwent open arthrotomy due to the formation of capsular fibrosis. Another patient was found to have residual loose bodies in the hip joint after the arthroscopic surgery, although there was

much improvement of symptoms after surgery. There are two explanations for these situations. First, the technique for hip arthroscopic surgery was still developing in this hospital at the time of the surgery. Second, the cause of this recurrence was the presence of residual loose bodies in the posteroinferior pouch of the hip joint.

The major long-term complication following PSC of the hip is degenerative changes in the hip.^(13,16,17) Schoeniger et al and Lim et al demonstrated that the rate of progression of osteoarthritis was higher in patients with mild osteoarthritis preoperatively than in those without osteoarthritis changes.^(13,16) In this series, only 1 patient, the one with the recurrence, had progressive degenerative changes in a 34-month follow-up.

The techniques for both open surgery and hip arthroscopic surgery have mature and are well developed in our hospital. In our experience, if the clinical and radiographic characteristics are typical of primary synovial chondromatosis, surgery is the definite treatment, and the approach could be open arthrotomy or arthroscopic surgery. Arthroscopic surgery can be performed initially because it is less invasive. However, when encountering difficulty in removal of loose bodies during the operation or if pre-operation assessment shows that adequate debridement is impossible, an arthrotomy is necessary. Acceptable results were achieved using the indications for open or arthroscopic surgery reported in this study. Irrespective of the surgical approach, the removal of all loose bodies combined with partial or complete synovectomy is mandatory. Patients who undergo surgery should be followed radiographically for evaluation of recurrence and development of hip arthritis.⁽¹⁷⁾

There are some limitations of the present study. First, the literature reports that the mechanical effects of delayed treatment combined with damage to the hip joint may result in subsequent hip joint degeneration, secondary hip subluxation and pathological fractures of the femoral neck.^(2,15,18) However, this study lacks a comparison of conservative and operative treatment. Second, this retrospective study included only 9 patients. The small number of the patients limited the analysis, so the true surgical results could not be determined. However, the incidence of synovial chondromatosis is low, and the present study included only patients admitted for sur-

gical intervention. We excluded patients who presented with no or mild symptoms and routine follow-up at the clinic. Further, a double-blinded, randomized, prospective large series study is necessary to identify whether open arthrotomy or arthroscopic surgery is appropriate and beneficial for PSC of the hip.

Conclusions

In summary, the present study reveals that optimal treatment of PSC of the hip is surgical intervention, even though the condition is insidious. Careful selection of patients, identification of different indications for different surgical treatments, and thorough preoperative imaging studies can help the patient achieve an early recovery with few complications, and prevent further recurrence of the disease.

REFERENCES

1. Murphy FP, Dahlin DC, Sullivan CR. Articular synovial chondromatosis. *J Bone Joint Surg Am* 1962;44:77-86.
2. Milgram JW. Synovial osteochondromatosis: A histopathological study of thirty cases. *J Bone Joint Surg Am* 1977;59:792-801.
3. Apte S, Athanasou NA. An immunohistological study of cartilage and synovium in primary synovial chondromatosis. *J Pathol* 1992;166:277-81.
4. Krebs VE. The role of hip arthroscopy in the treatment of synovial disorders and loose bodies. *Clin Orthop Relat Res* 2003;406:48-59.
5. Kelly BT, Williams RJ 3rd, Philippon MJ. Hip arthroscopy: current indications, treatment options and management issues. *Am J Sports Med* 2003;31:1020-37.
6. Boyer T, Dorfmann H. Arthroscopy in primary synovial chondromatosis of hip. Description and outcome of treatment. *J Bone Joint Surg Br* 2008;90:314-8.
7. Kellgren JH, Lawrence JS. Radiological assessment of osteo-arthritis. *Ann Rheum Dis* 1957;16:494-502.
8. Hardinge K. The direct lateral approach to the hip. *J Bone Joint Surg Br* 1982;64:17.
9. Chiang CW, Chan YS, Hsu KY, Chen WJ. Revision arthroscopic surgery for synovial chondromatosis of the hip: a case report and literature review. *J Orthop Surg Taiwan* 2007;24:1-5
10. Chen CY, Chen AC, Chang YH, Fu TS, Lee MS. Synovial chondromatosis of the hip: management with arthroscopy-assisted synovectomy and removal of loose bodies: report of two cases. *Chang Gung Med J* 2003;26:208-14.
11. Knoeller SM. Synovial osteochondromatosis of the hip joint. Etiology, diagnostic investigation and therapy. *Acta Orthop Belg* 2001;67:201-10.
12. Schoeniger R, Naudie DD, Siebenrock KA, Trousdale RT, Ganz R. Modified complete synovectomy prevents recurrence in synovial chondromatosis. *Clin Orthop Relat Res* 2006;451:195-200.
13. Lim SJ, Chung HW, Choi YL, Moon YW, Seo JG, Park YS. Operative treatment of primary synovial chondromatosis of the hip. *J Bone Joint Surg Am* 2006;88:2456-64.
14. Okada Y, Awaya G, Ikeda T, Tada H, Kamisato S, Futami T. Arthroscopic surgery for synovial chondromatosis of the hip. *J Bone Joint Surg Br* 1989;71:198-9.
15. Thomas Byrd JW, Jones KS. Hip arthroscopy in the supine position. *Oper Tech Sports Med* 2002;10:184-95.
16. Sakellariou A, Jonestone DJ, Pringle JA. Synovial chondromatosis presenting as a pathological fracture of the femoral neck in an 89-year-old woman—a case report. *Acta Orthop Scand* 1998;69:640-1.
17. Adelani MA, Wupperman RM, Holt GE. Benign synovial chondromatosis. *J Am Acad Orthop Surg* 2008;16:268-75.
18. Hardacker J, Mindell ER. Synovial chondromatosis with secondary subluxation of the hip. A case report. *J Bone Joint Surg Am* 1991;73:1405-7.

以關節切開手術與關節鏡手術治療 髖關節原發性滑膜軟骨瘤病的臨床經驗

游宜勳 詹益聖 李炫昇 施信農

- 前言：**原發性滑膜軟骨瘤病通常好發於身體的大關節處，如膝關節與髖關節。而使用適當的手術方式來成功治療髖關節原發性滑膜軟骨瘤病，在文獻上仍有爭議。
- 方法：**本篇回顧性的研究是收集自 2000 年至 2005 年裡，因為有症狀的髖關節原發性滑膜軟骨瘤病，而接受手術治療的病患。藉由定義不同的適應症，我們選擇不同的手術方式（關節切開手術或是關節鏡手術）進行治療。
- 結果：**我們收集的 9 位病患中，有 4 位接受髖關節切開手術，有 5 位病患接受髖關節關節鏡手術治療。平均的追蹤時間為 24.9 個月（範圍：12 至 50 個月）。所有的病患在手術期間與手術之後皆無併發症產生。其中有一位病患在接受髖關節關節鏡手術 2 年之後有復發的情形。除了在復發的病患持有持續性的髖關節退化情形之外，其餘開刀病患的髖關節，在開刀之後都維持穩定的情形。在手術之後的 12 個月，所有病患的 Harris Hip Score 平均為 93.7 分（範圍：90 至 99 分）。
- 結論：**以手術的方式來治療髖關節原發性滑膜軟骨瘤病，對這些病患是有幫助；藉由確認手術的適應症，選擇適當的手術方式可以使病患較快的恢復與較少的復發。
(長庚醫誌 2011;34:101-8)

關鍵詞：滑膜軟骨瘤病，關節切開術，關節鏡手術

長庚醫療財團法人林口長庚紀念醫院 骨科部 關節重建科；長庚大學 醫學院

受文日期：民國99年4月12日；接受刊載：民國99年7月16日

通訊作者：施信農醫師，長庚醫療財團法人林口長庚紀念醫院 骨科部 關節重建科。桃園縣333龜山鄉復興路5號。

Tel.: (03)3281200轉2420; Fax: (03)3274564; E-mail: aronc@cgmh.org.tw